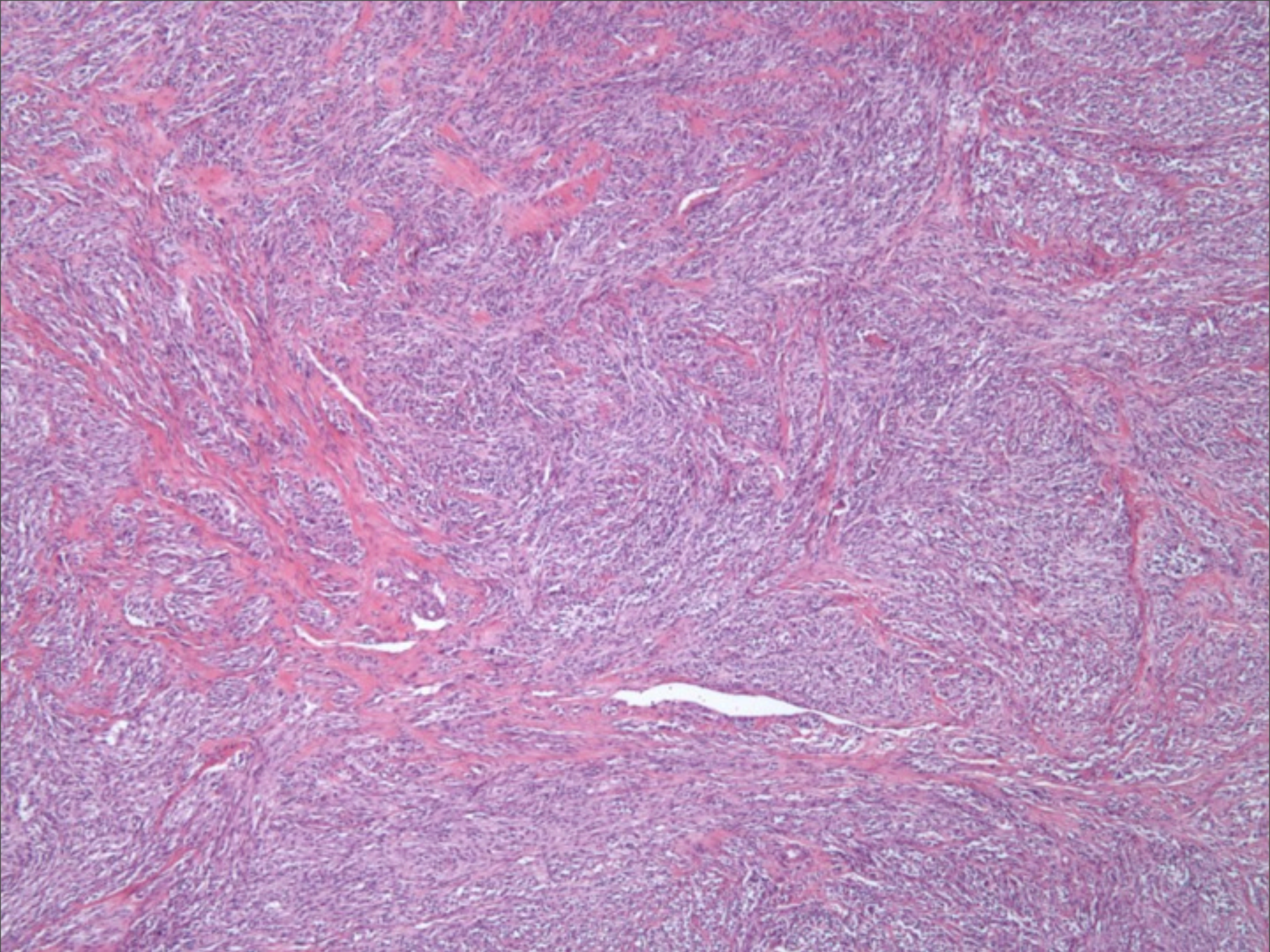
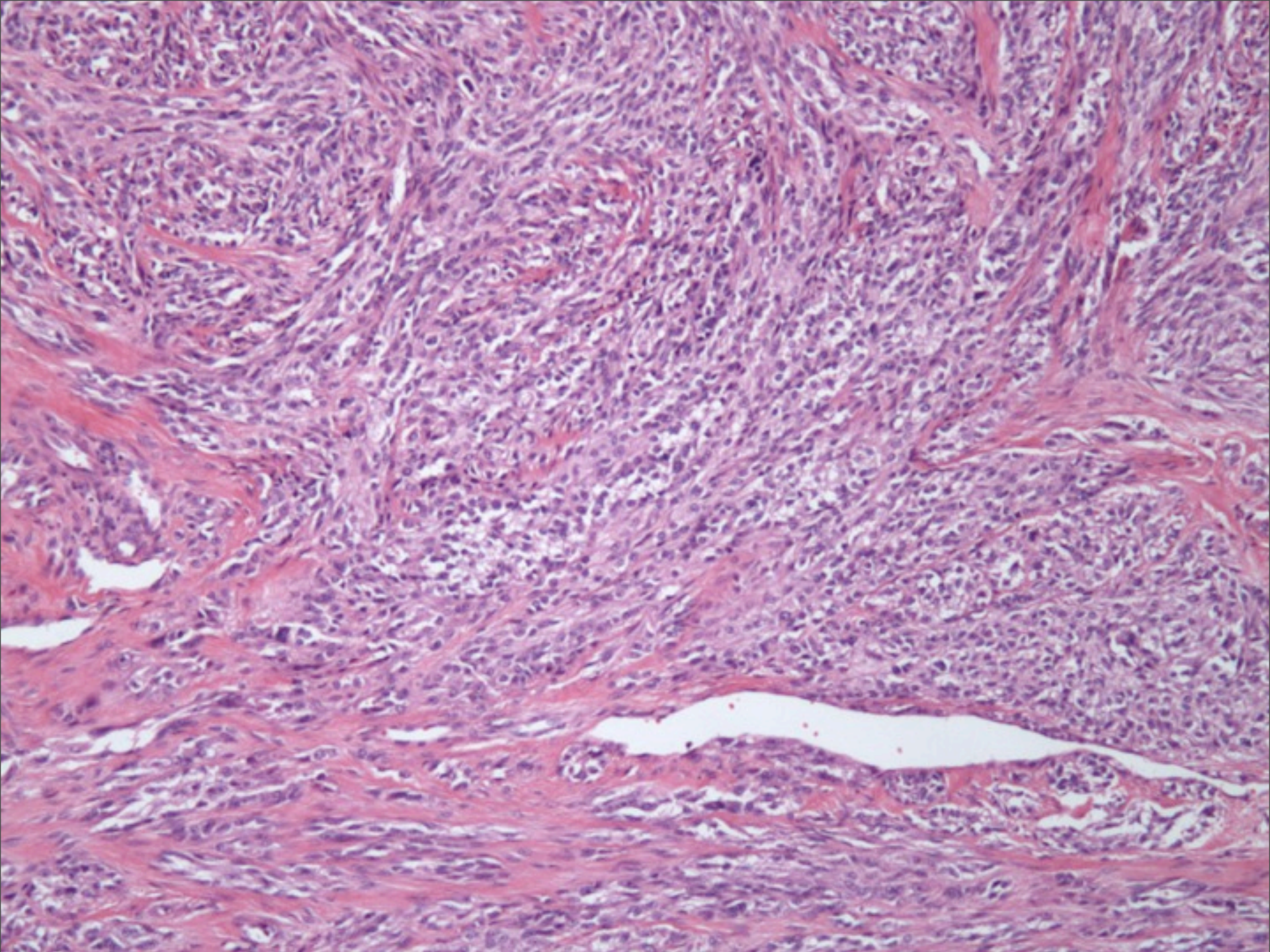
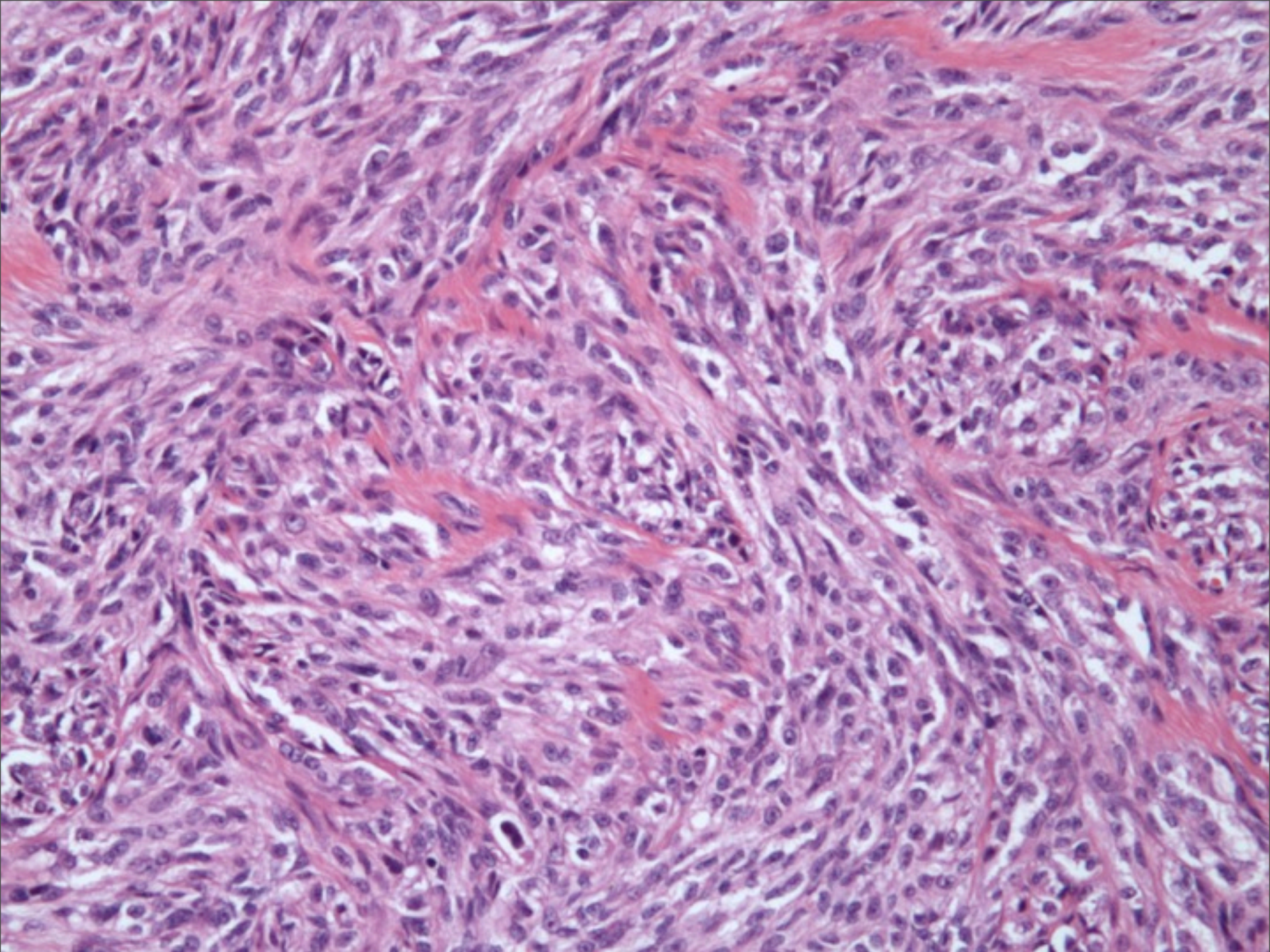


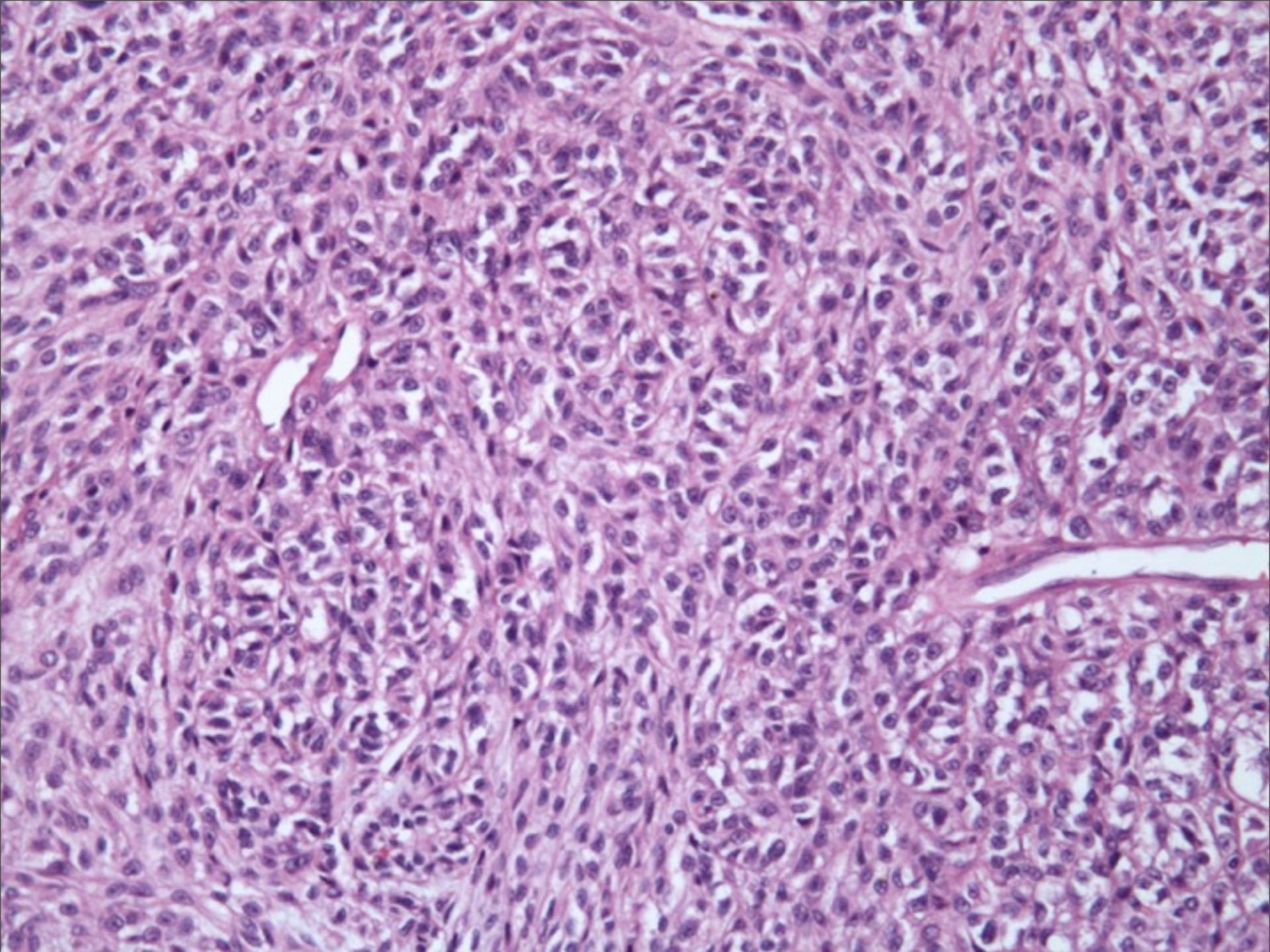
Is It Melanoma? Should It Be?

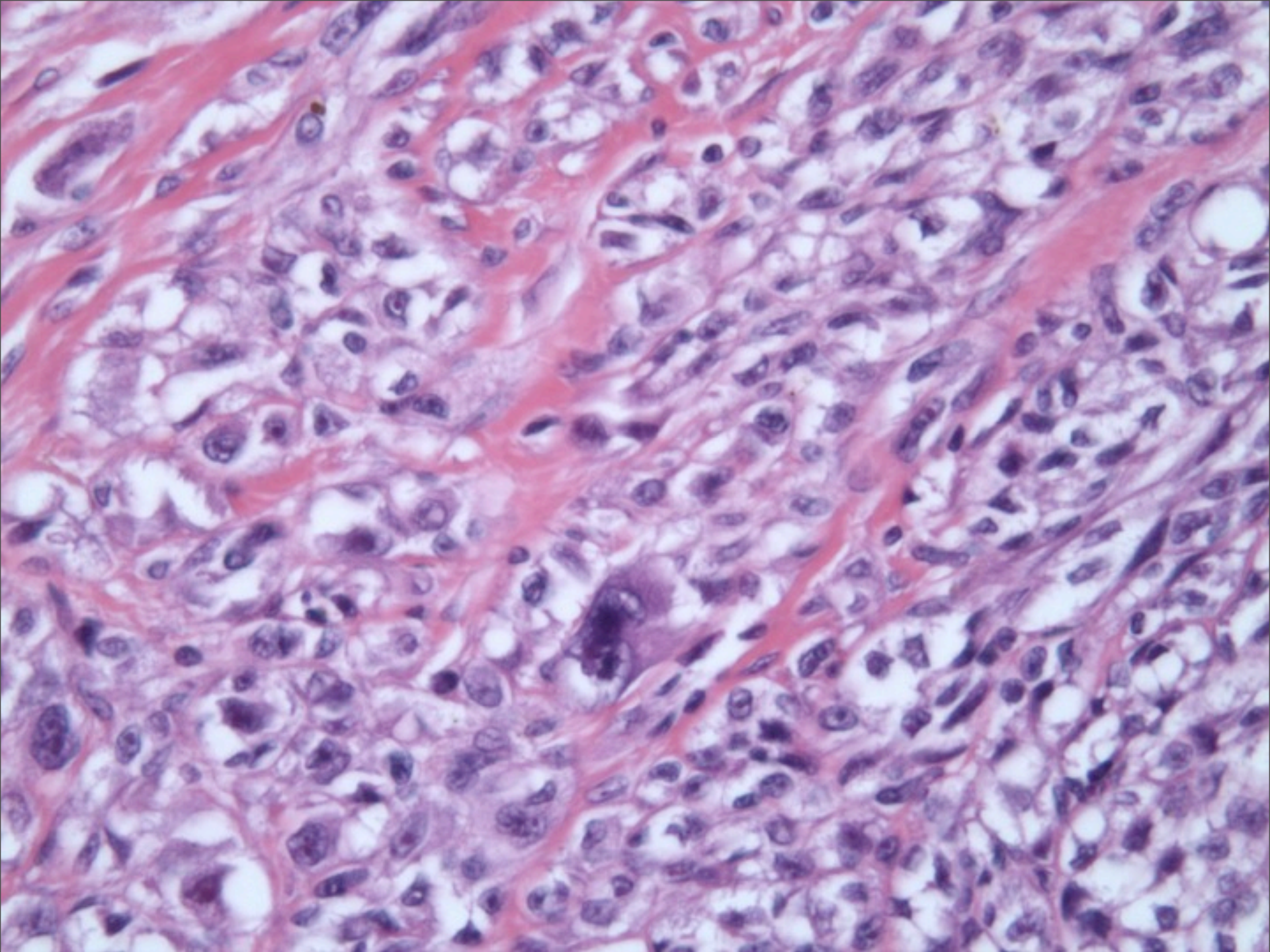
Paul K. Shitabata, M.D.
Dermatopathology Institute

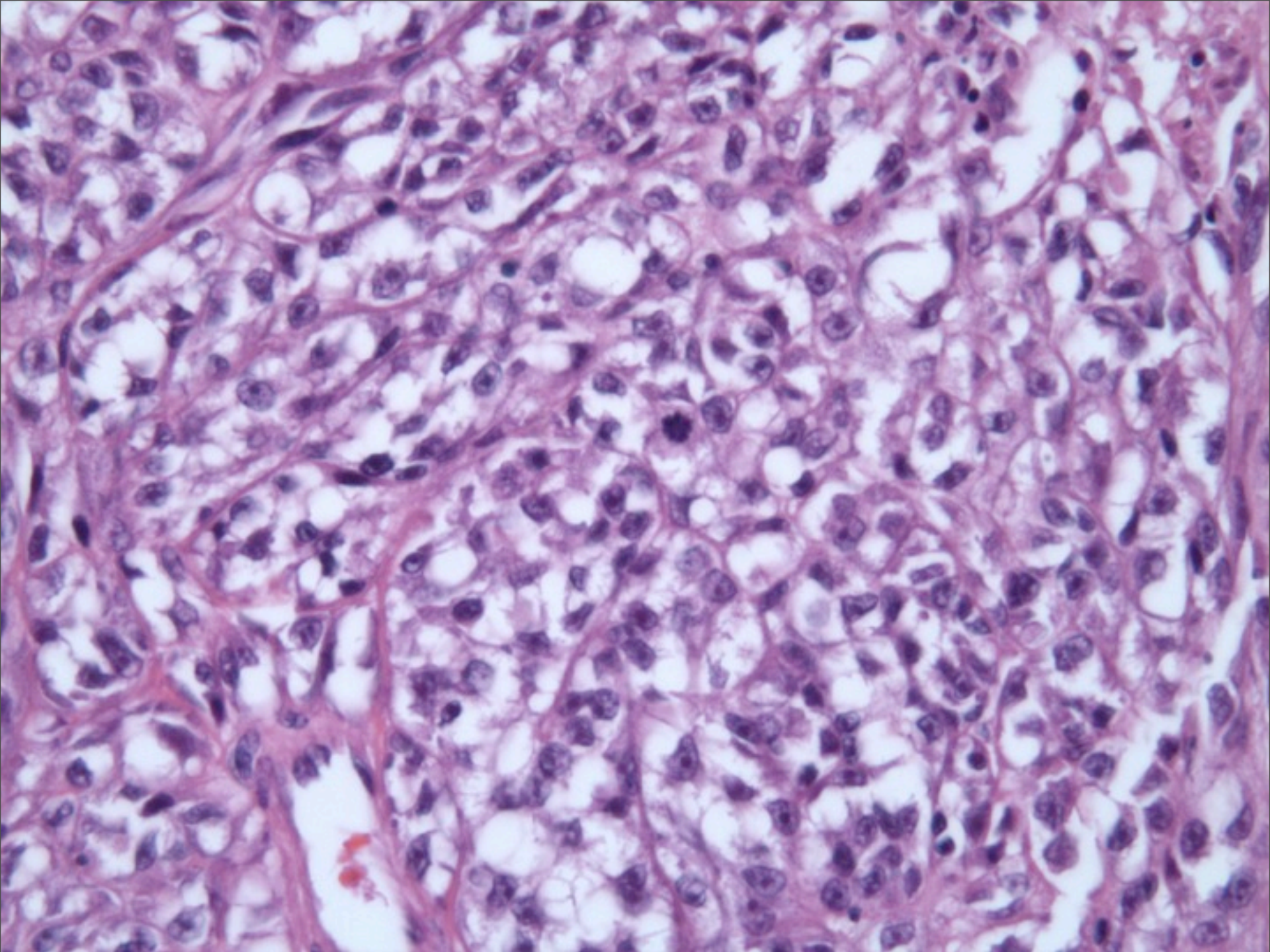






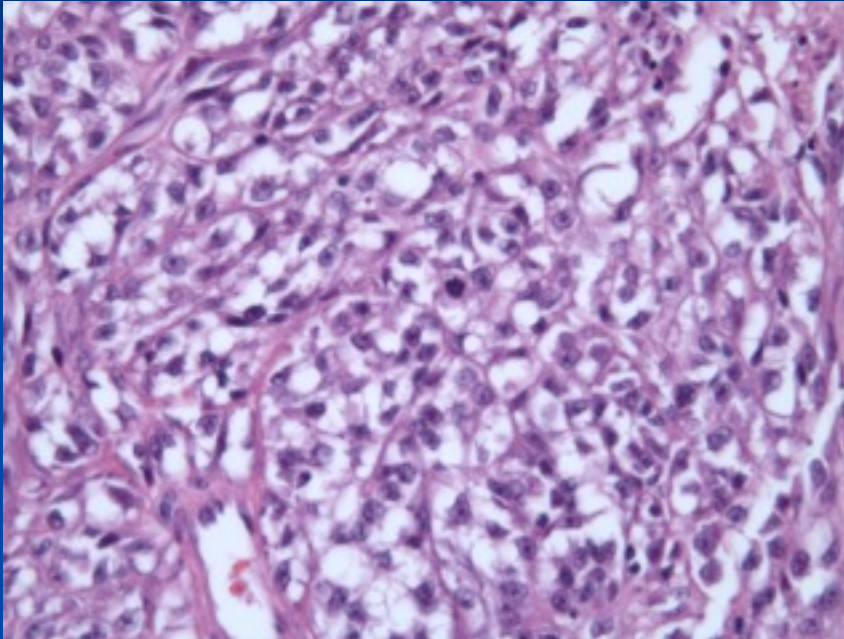




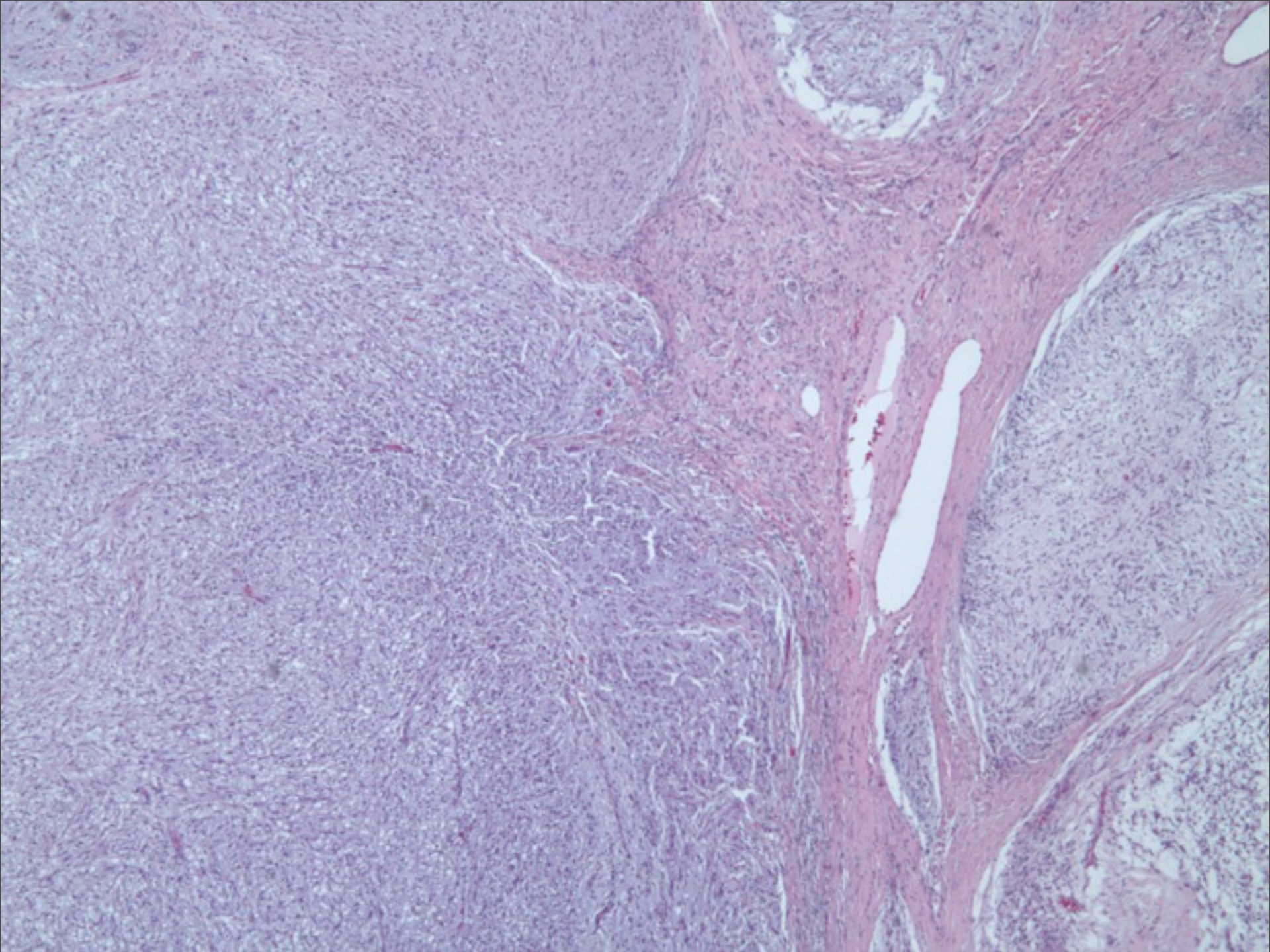


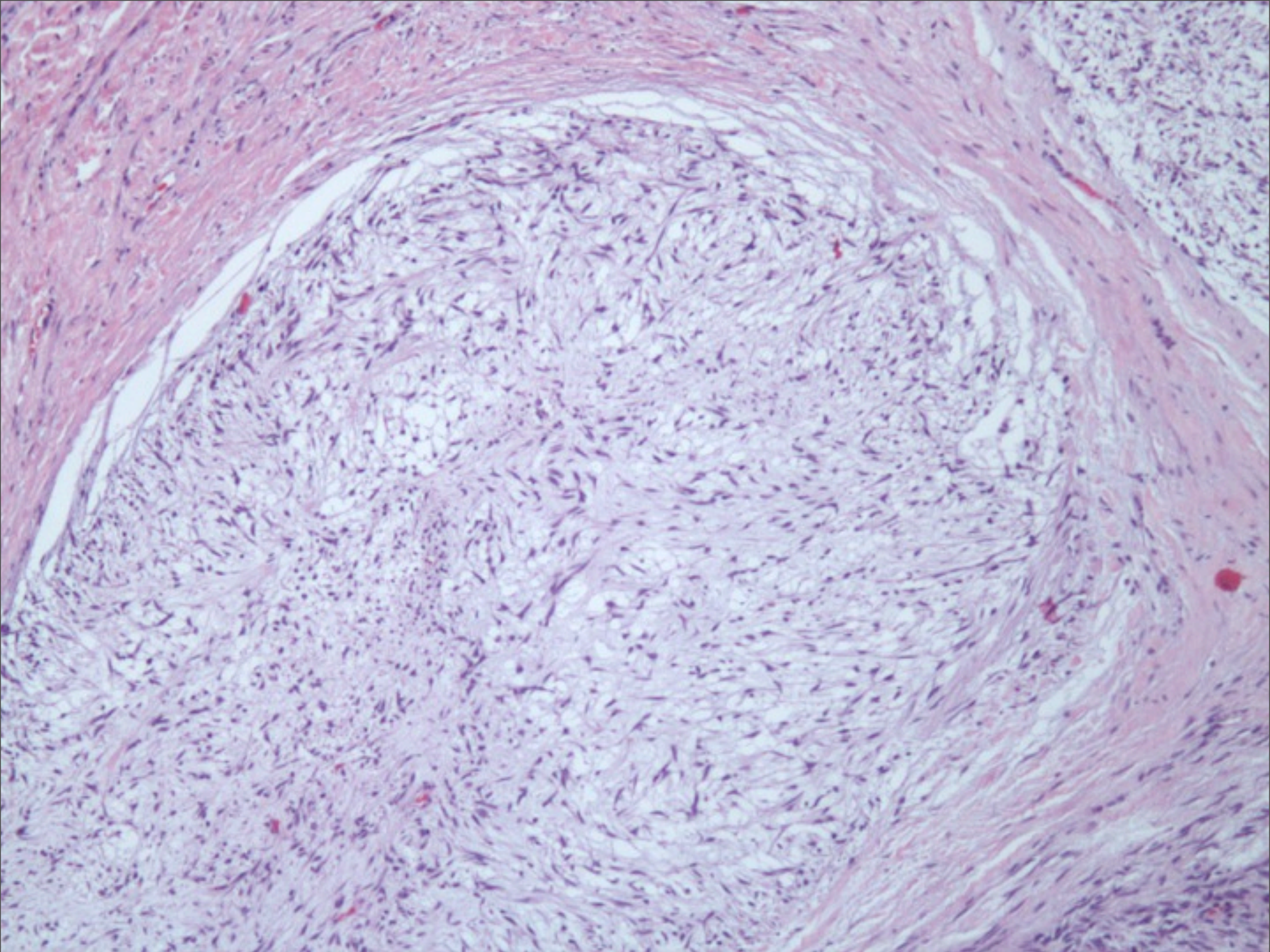
Clear Cell Sarcoma (Malignant Melanoma of Soft Parts)

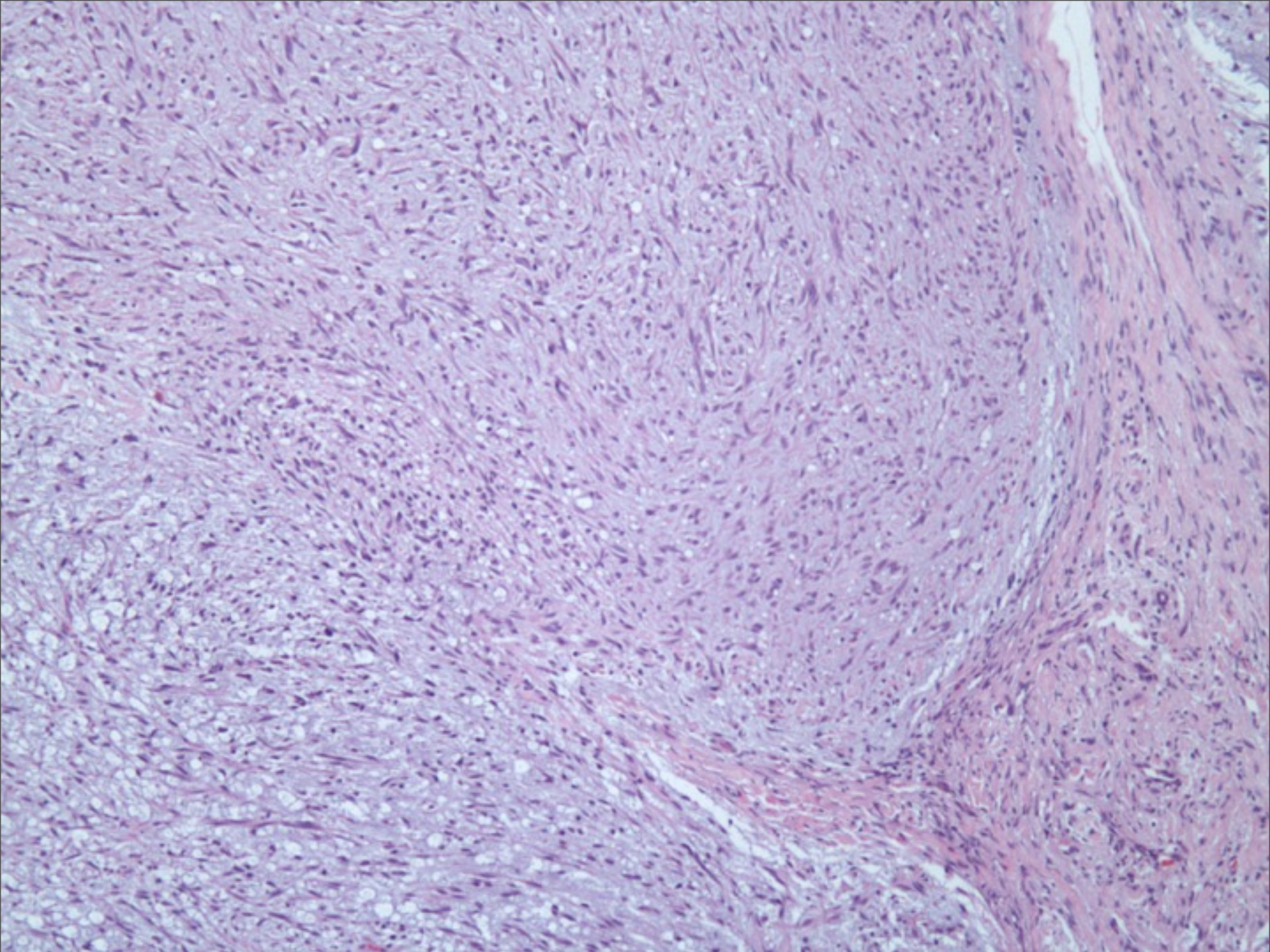
Histopathology



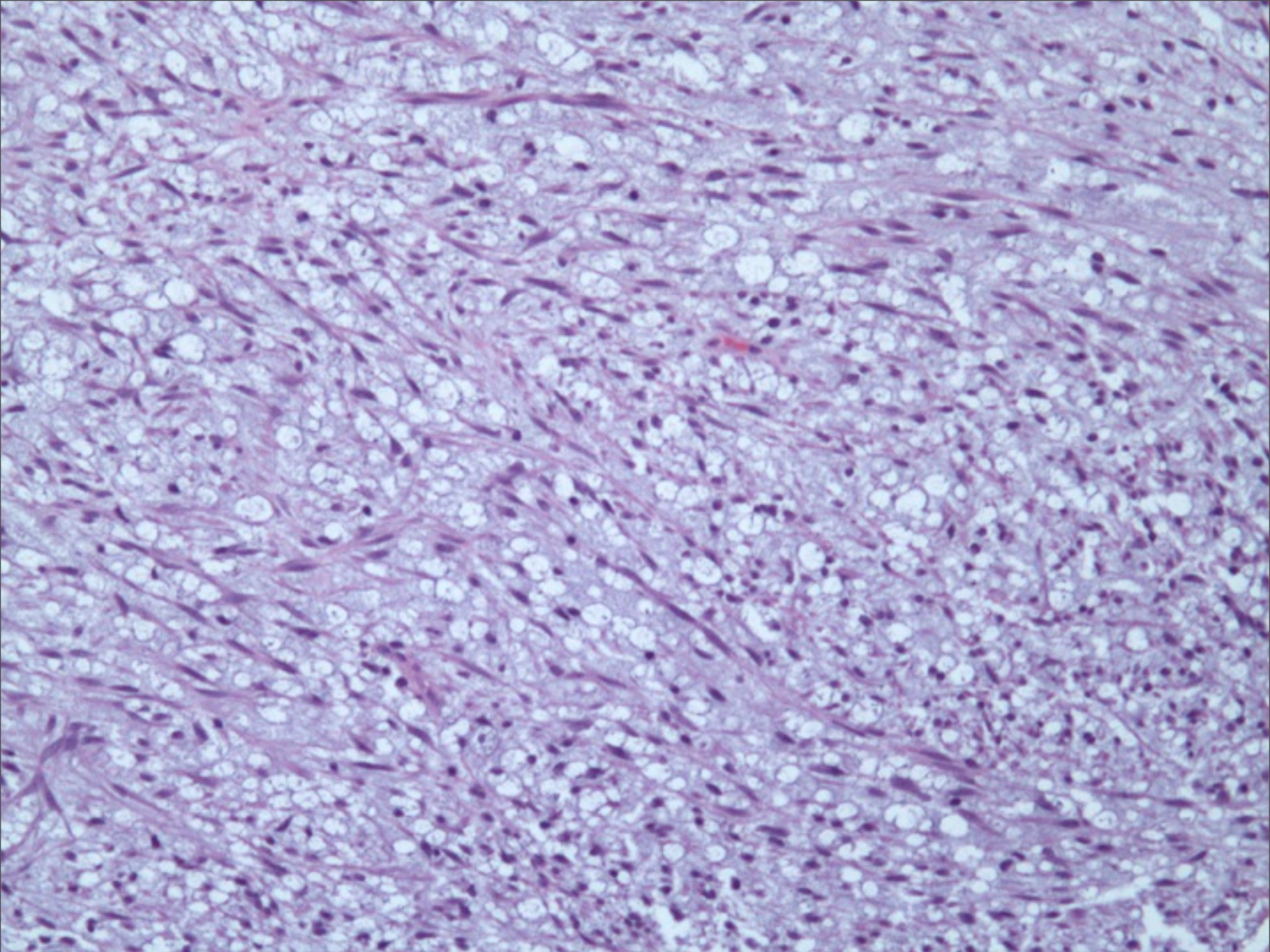
- Uniform fascicles of clear cells
- MF rare <2-3/10hpf
- Rarely melanin pigment
- Unique translocation $t(12;22)$ (q13;q12) in >75% of cases
 - Fuses ATF-1 with EWS
- S100+, variable MART1, HMB-45
- Melanomas by EM

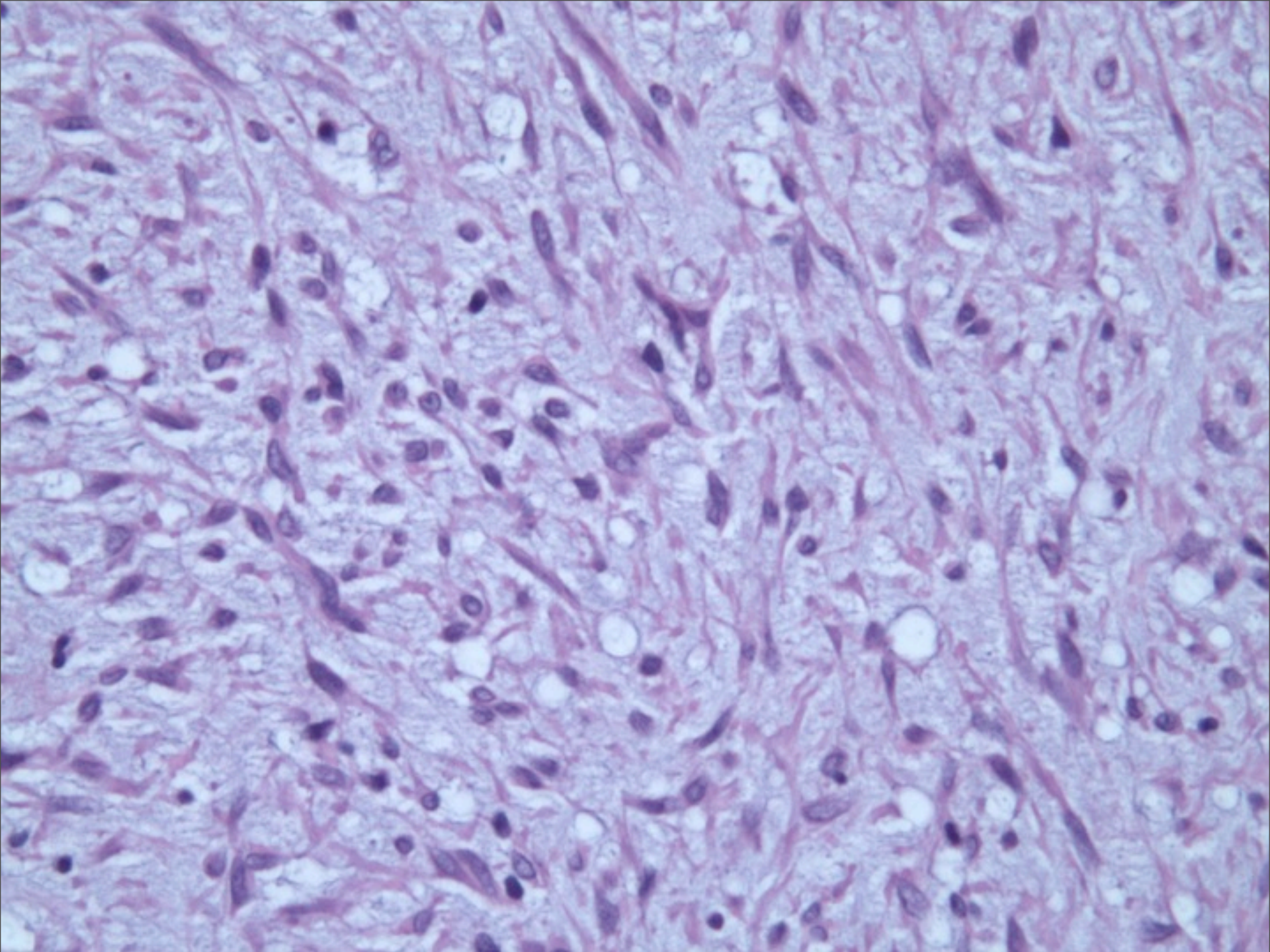


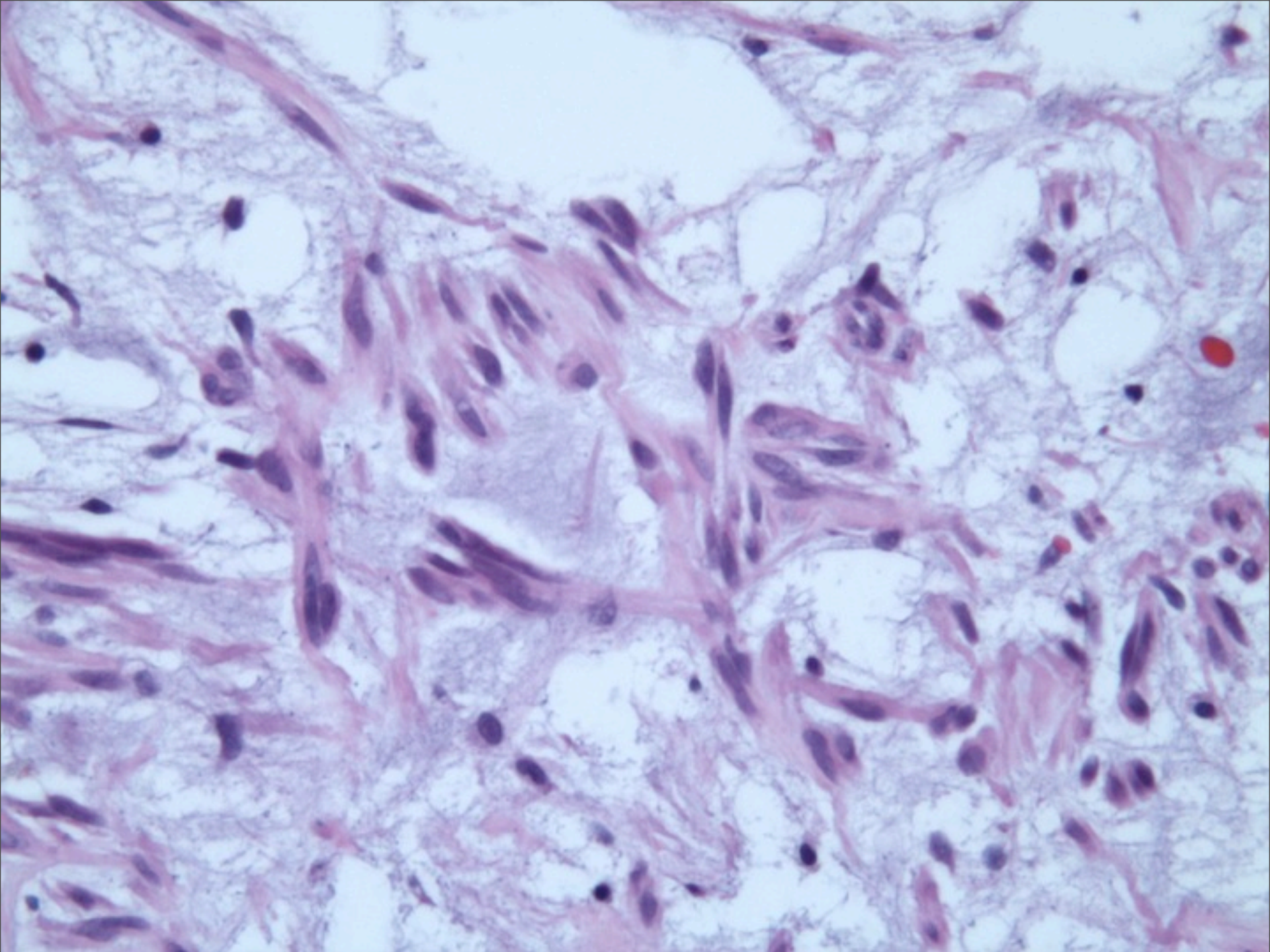




Thursday, May 23, 13

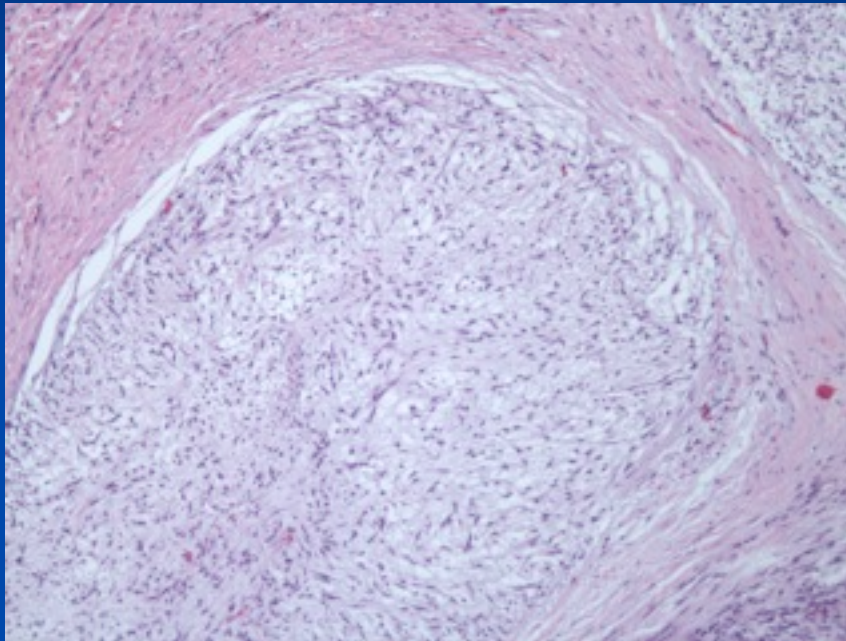




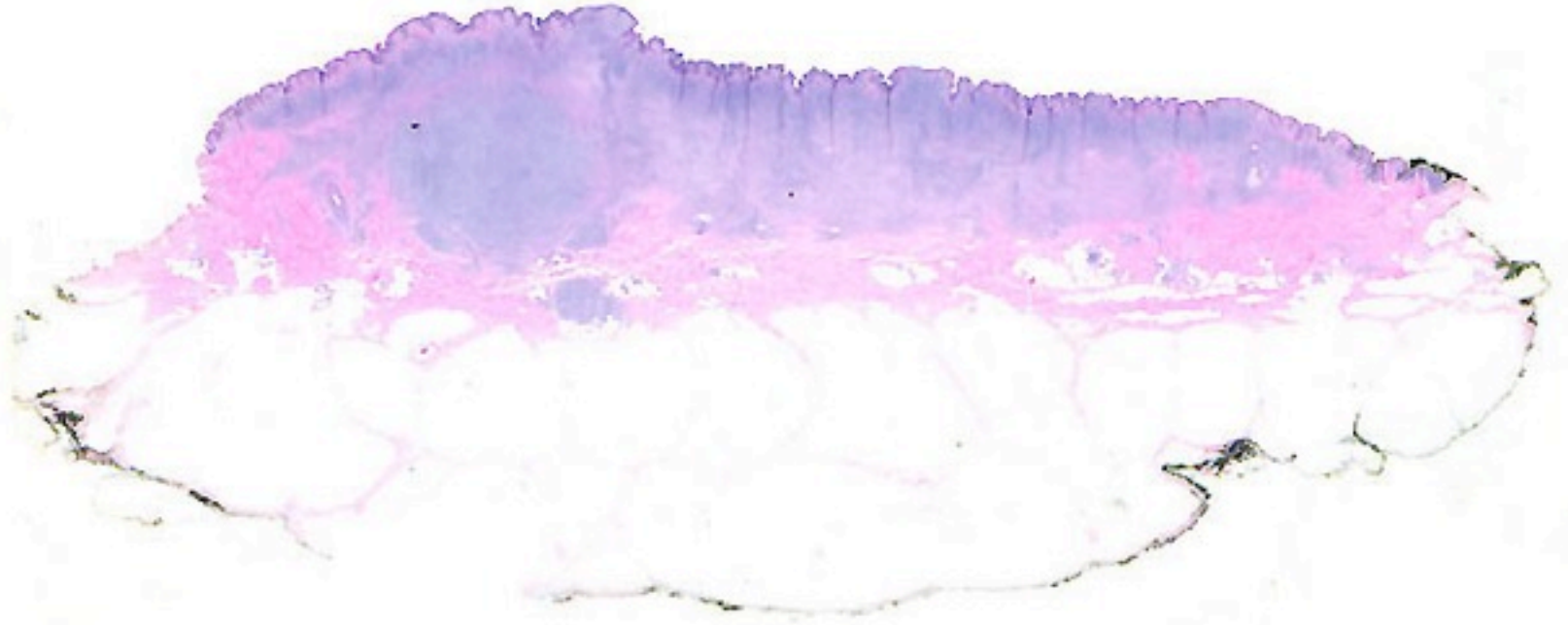

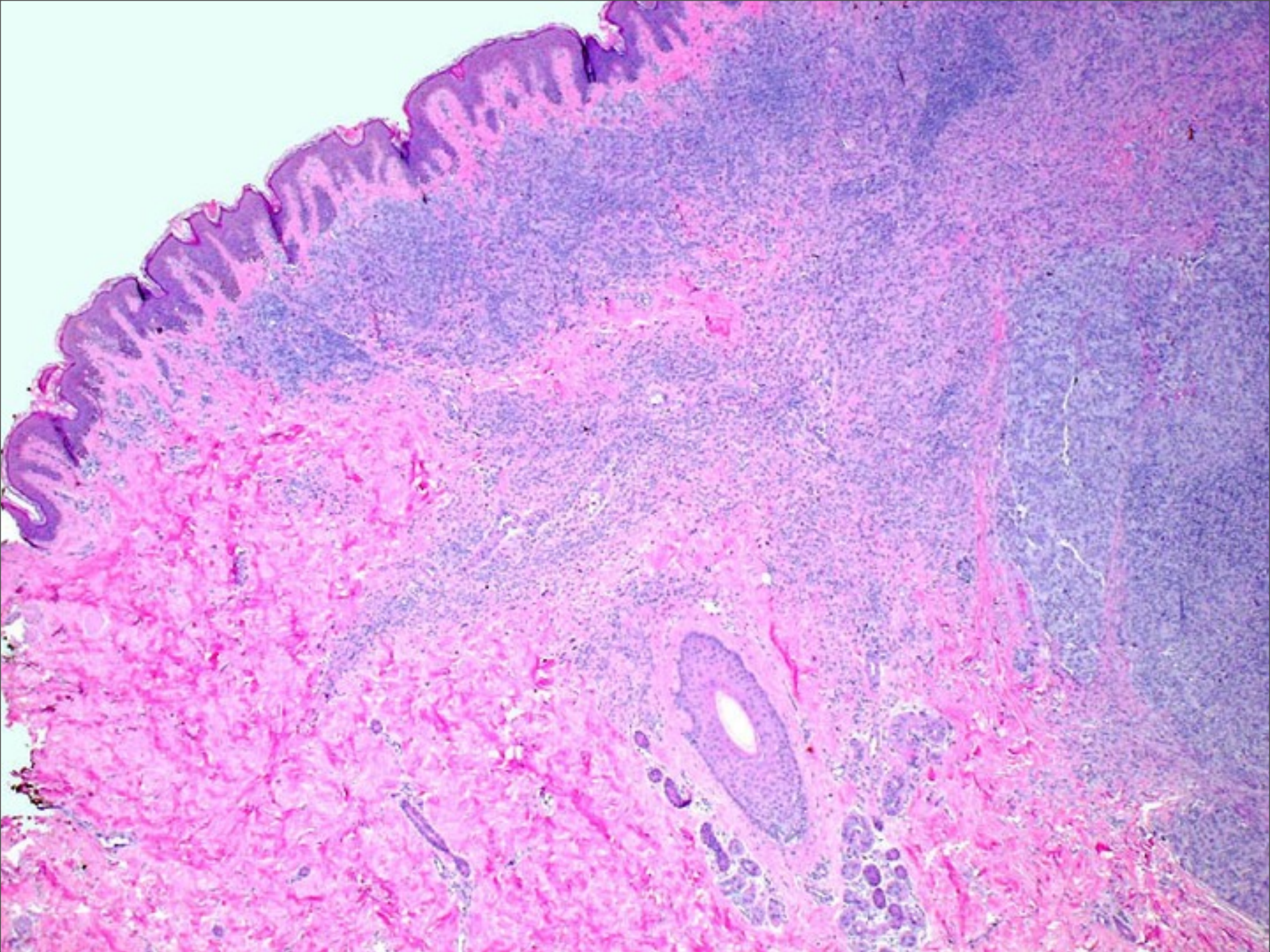
Neurothekeoma

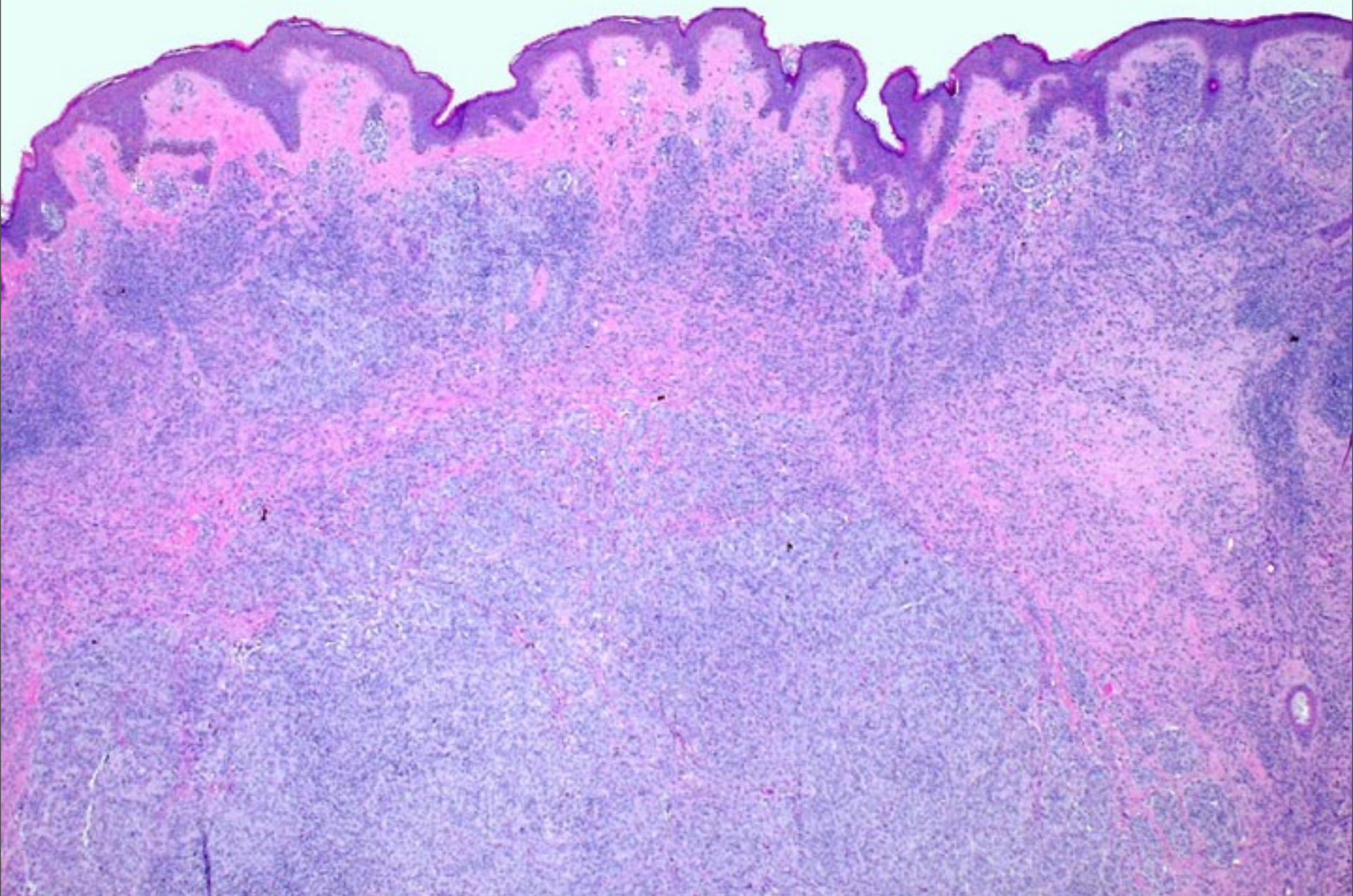
Histopathology

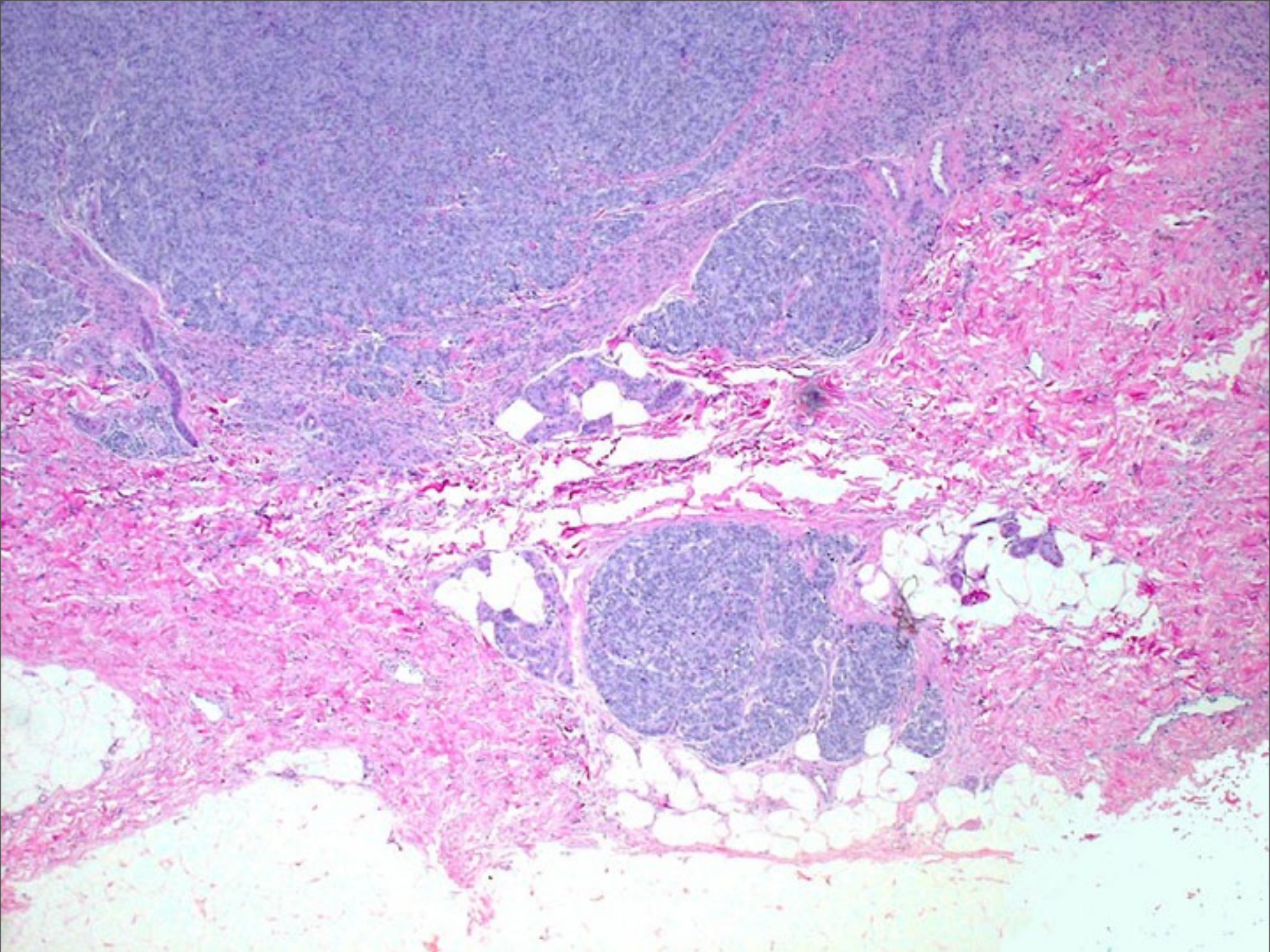


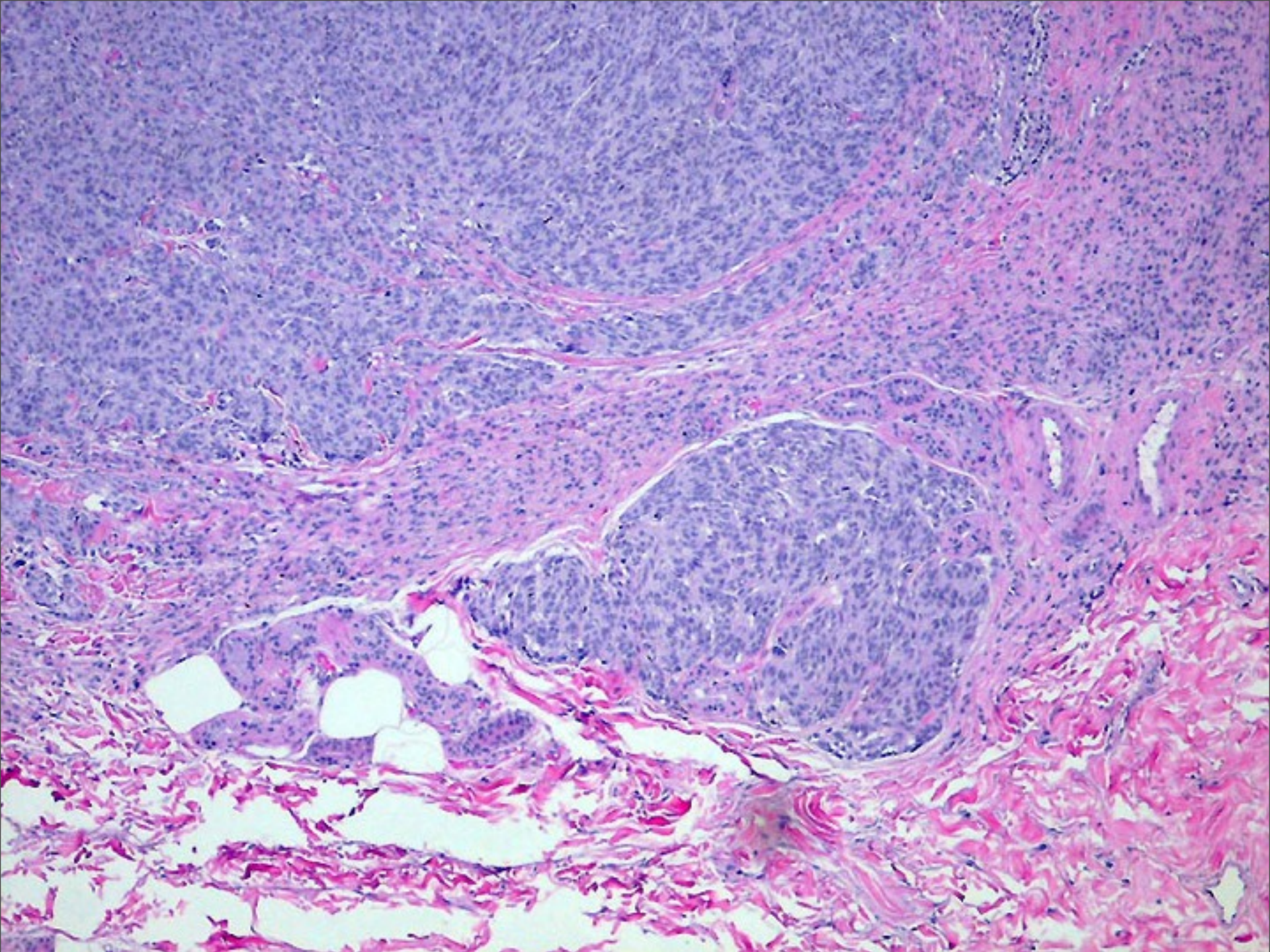
- Usually superficial dermis but may extend to fat or skeletal muscle
- Prominent fibrotic septae
- Lobules of spindle cells in myxoid matrix
- Minimal pleomorphism and rare MF
- S100+, Mart1 and HMB45 -

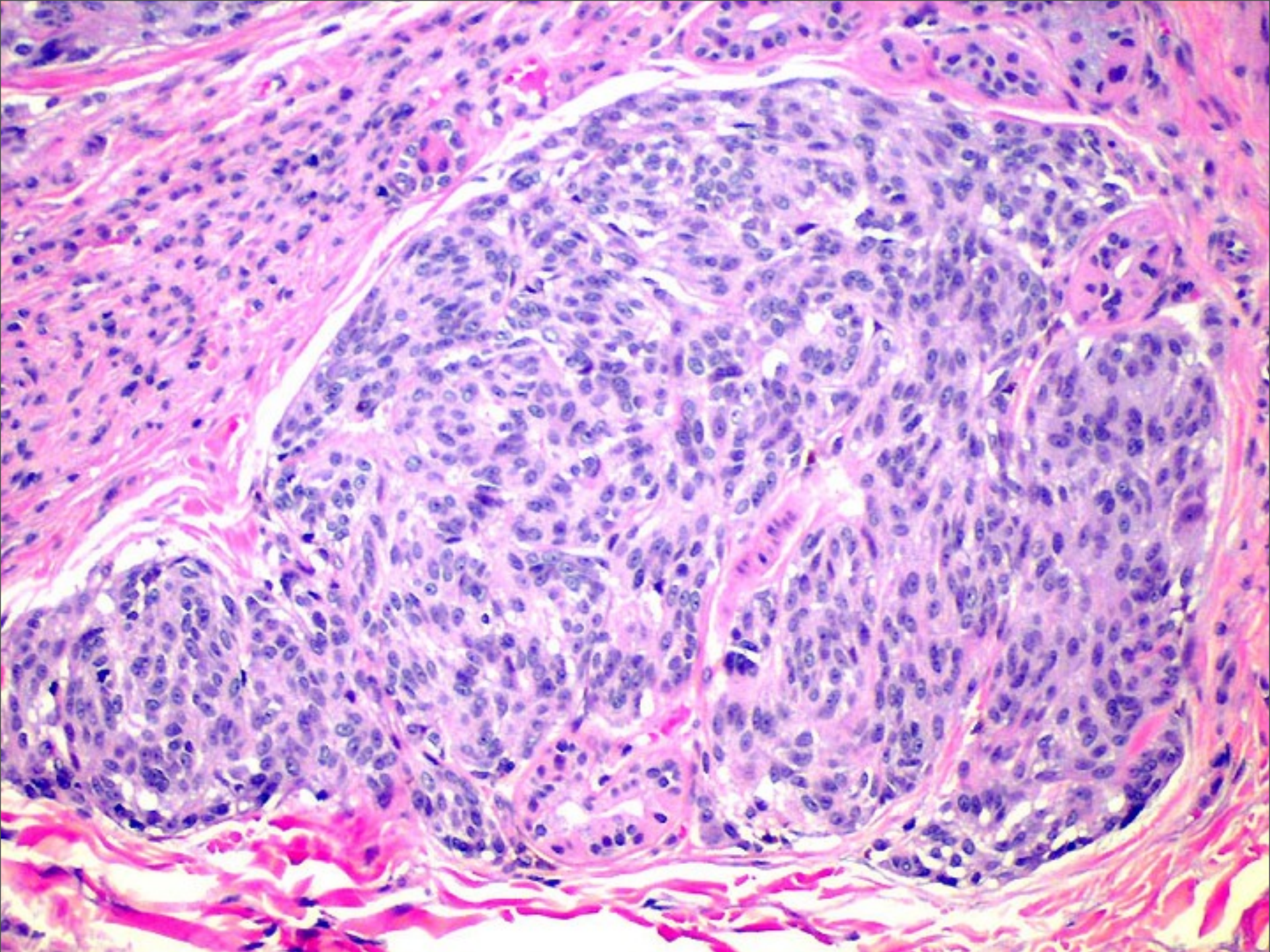


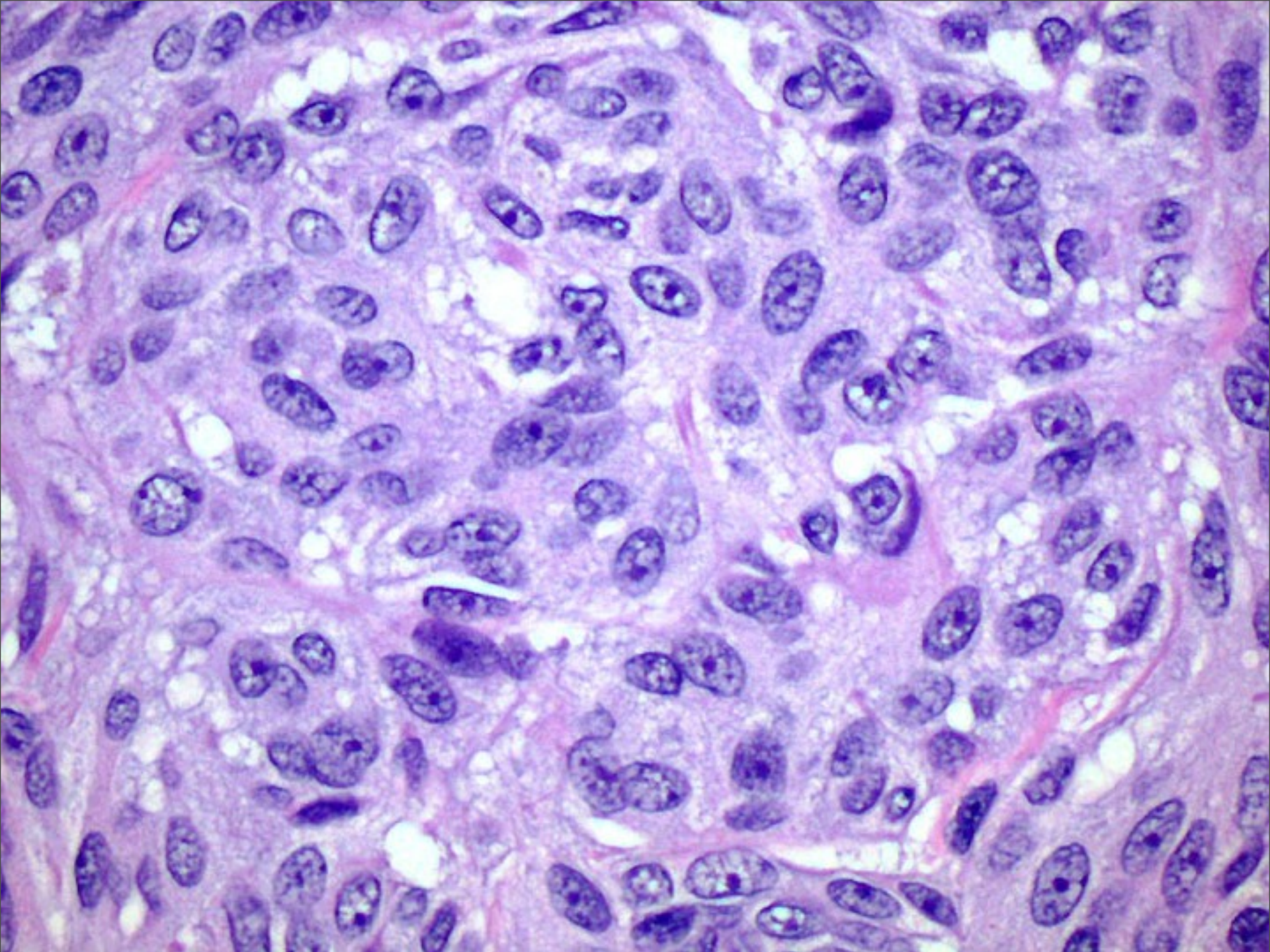


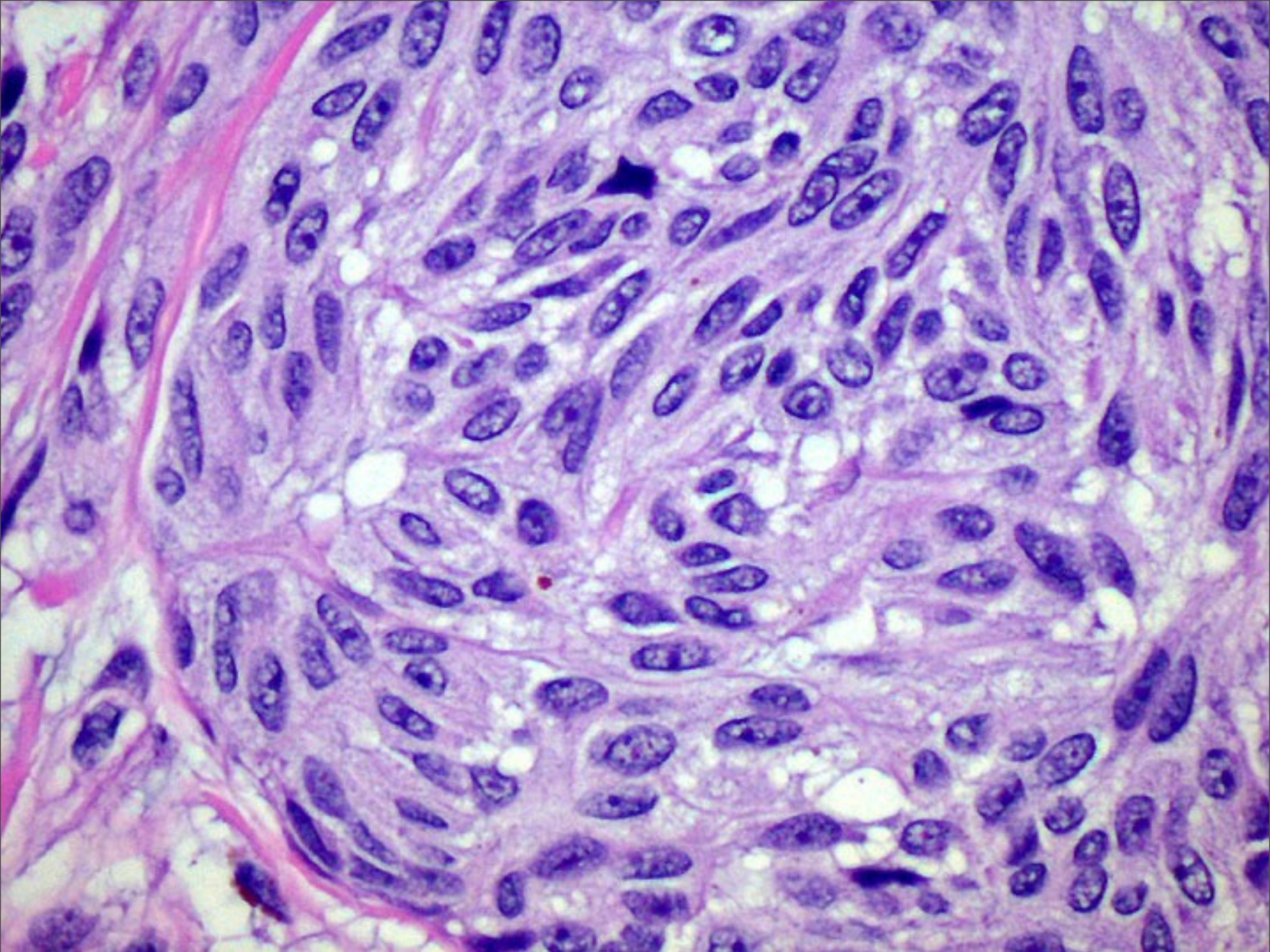






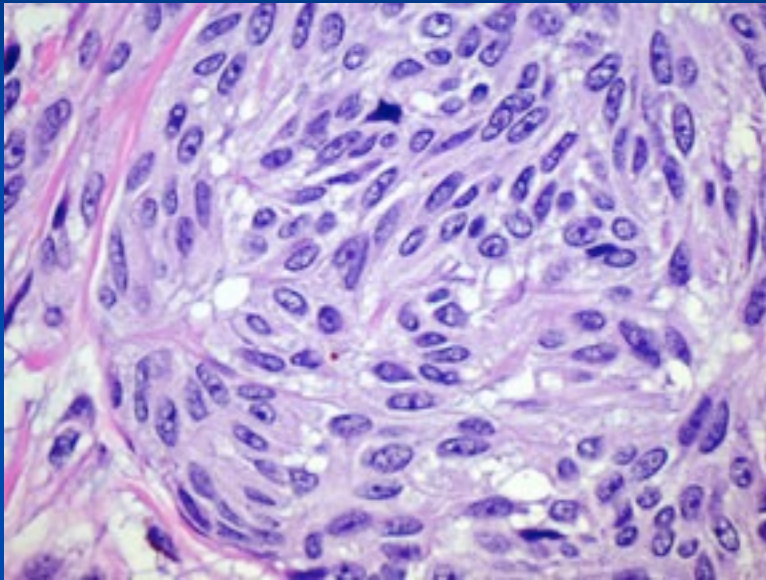




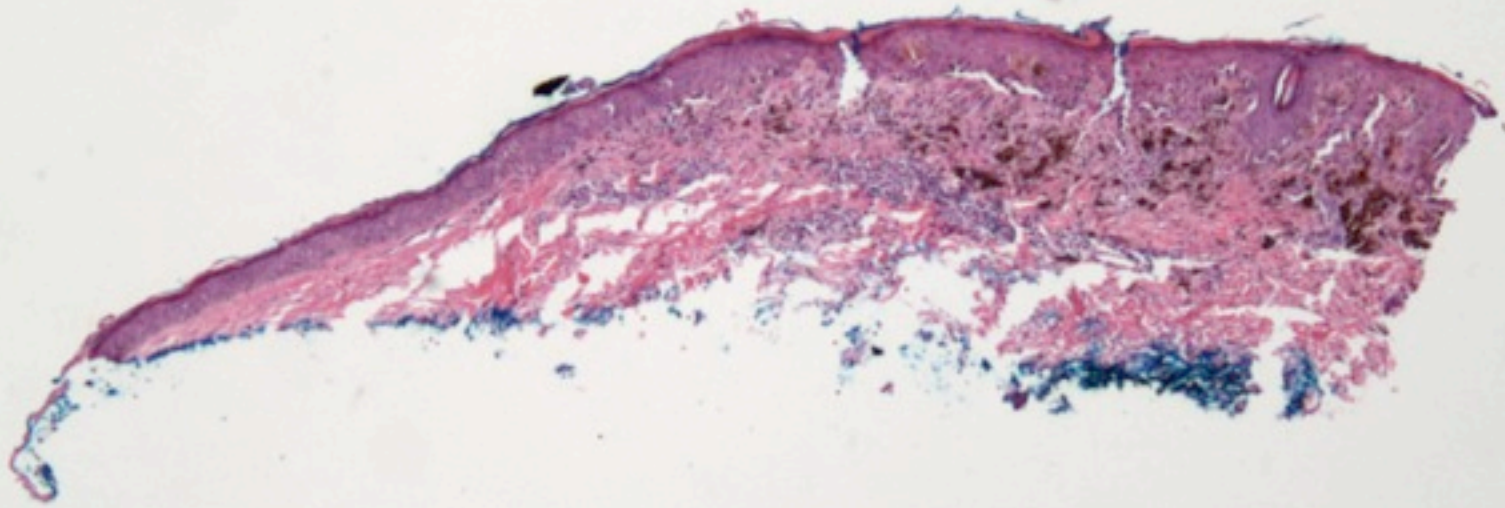


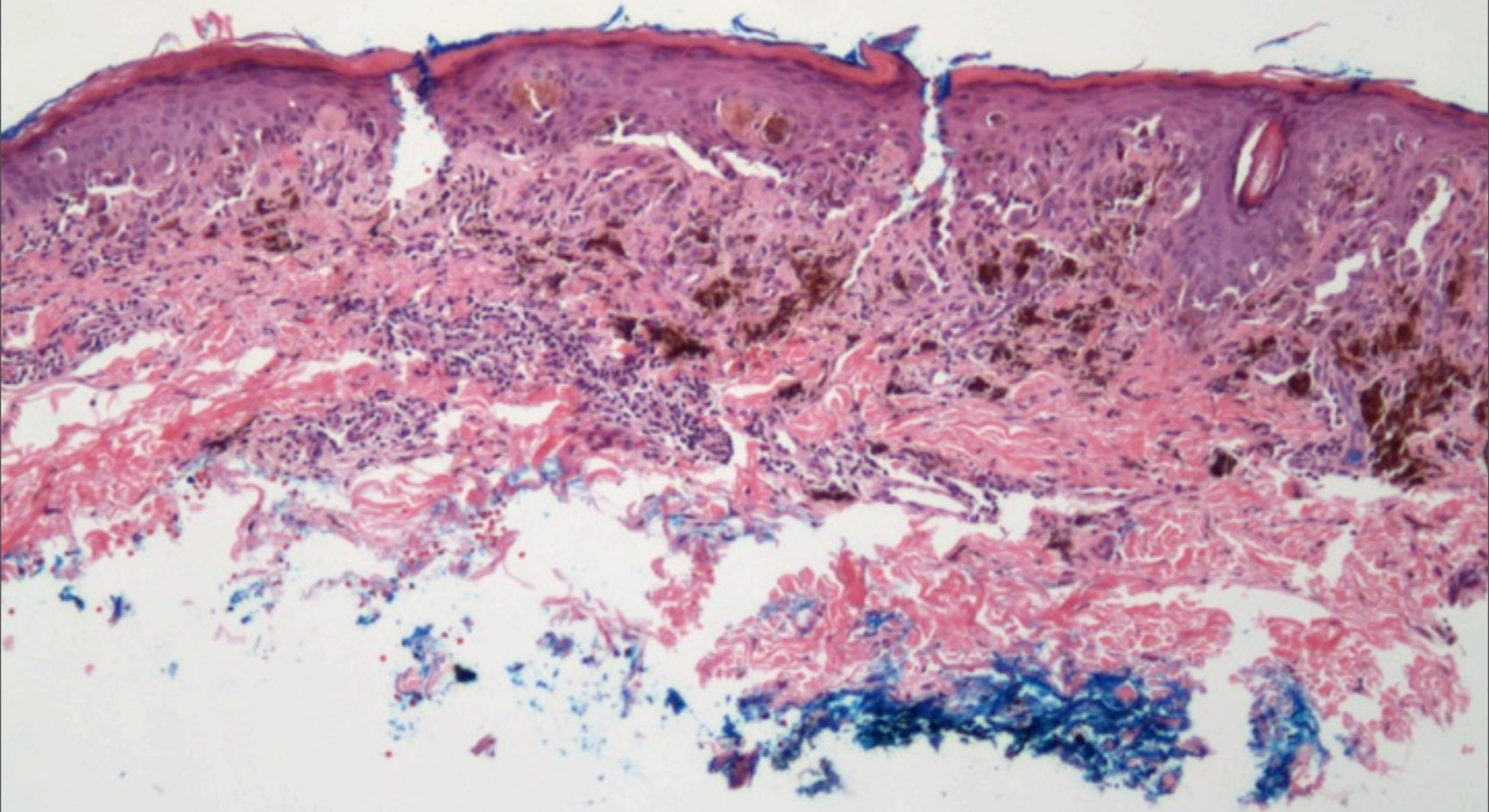
Cellular Nodule arising within a

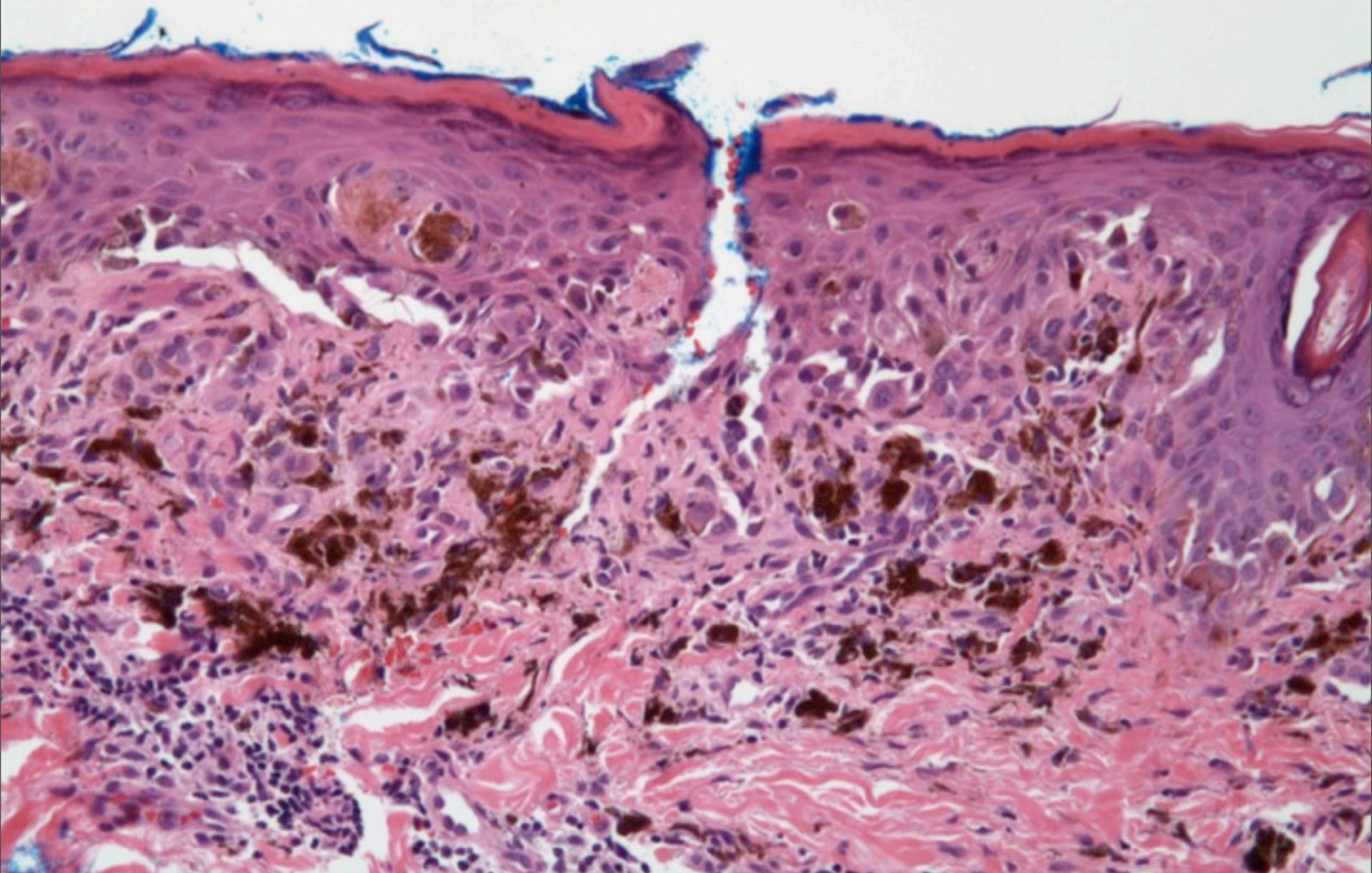
Histopathology

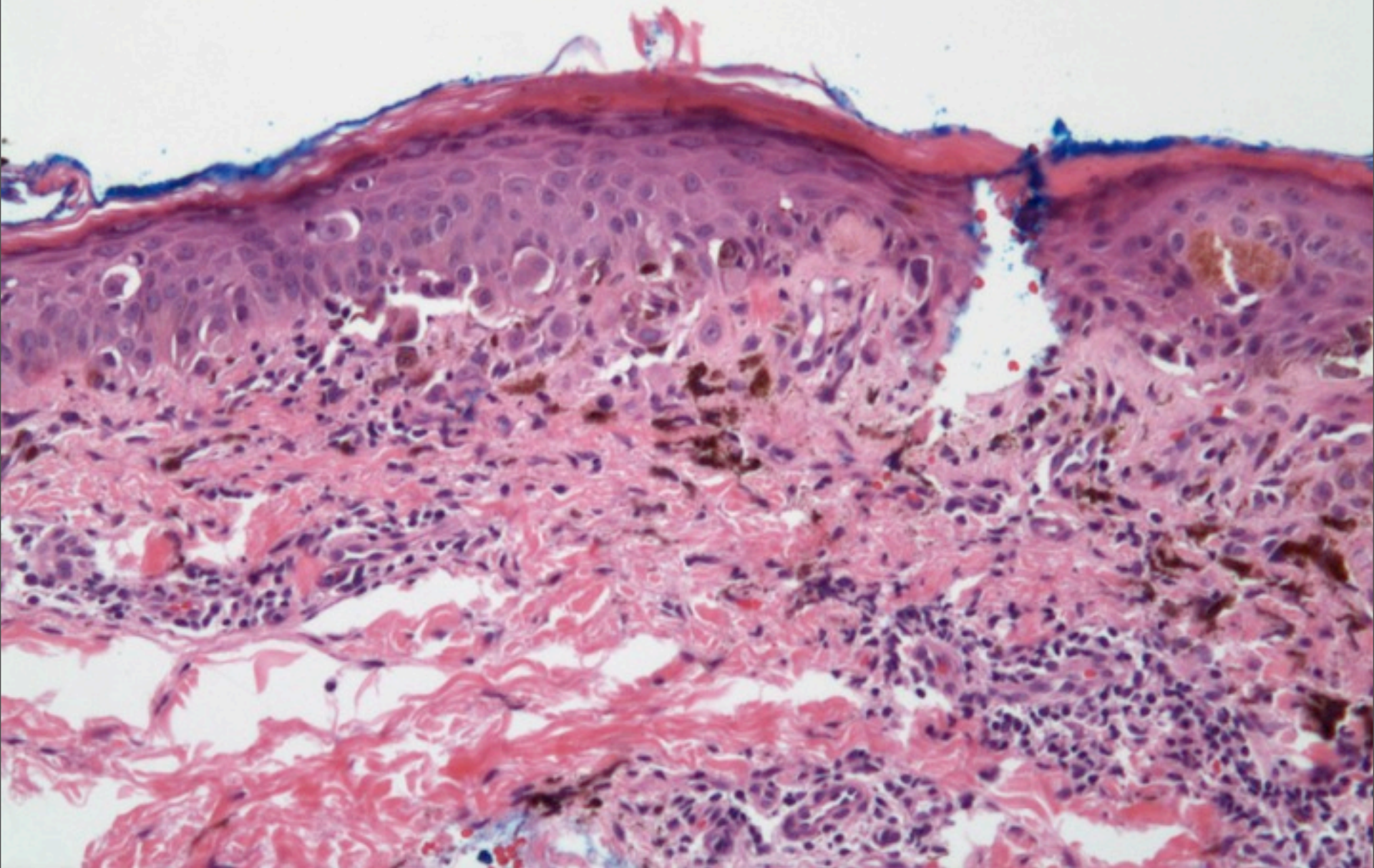


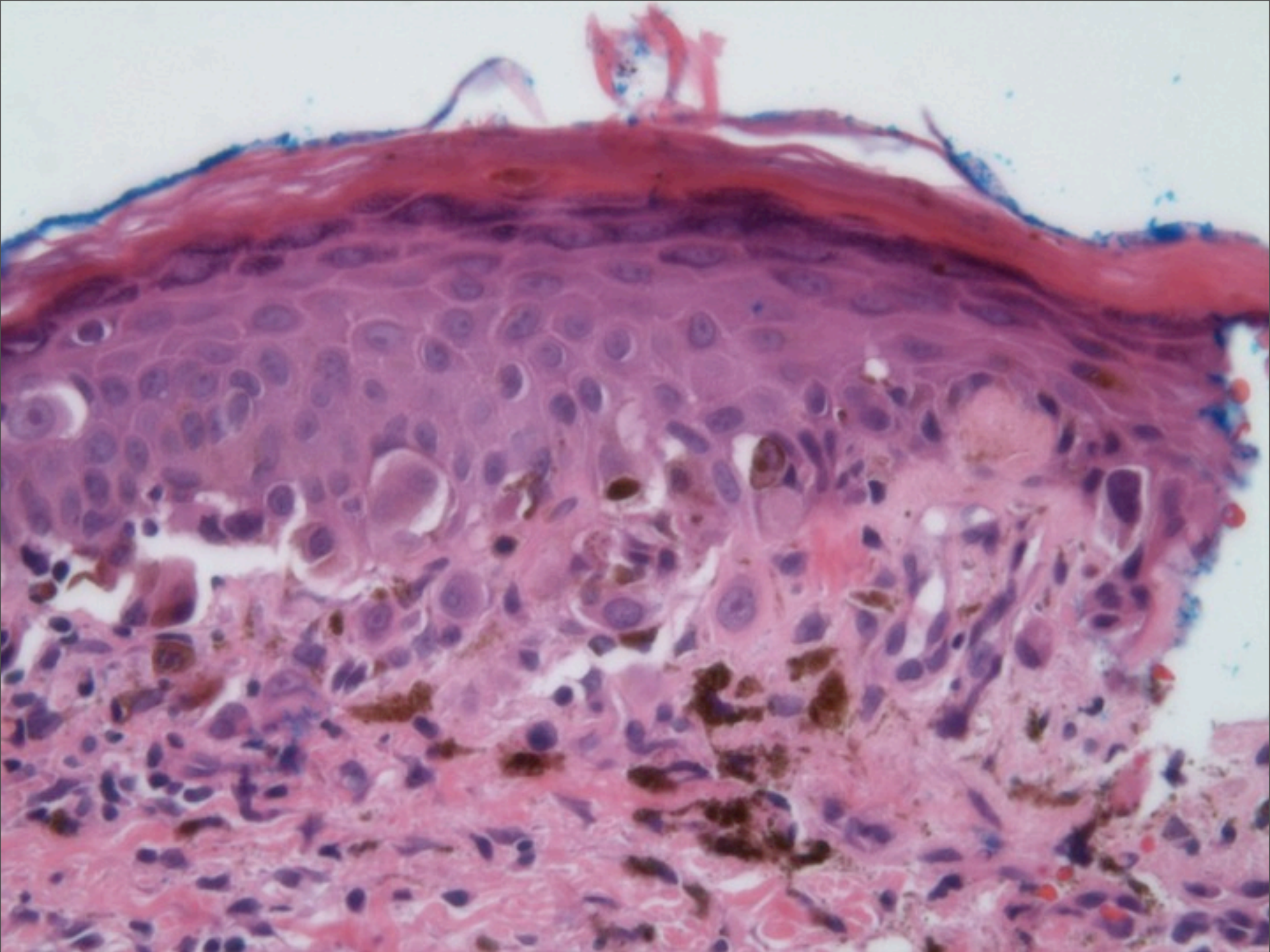
- Symmetric
- Small uniform nucleoli and delicate chromatin
- Pigmentation uniform
- Rare and always typical MF
- No necrosis
- Usually no inflammation unless undergoing halo phenomenon

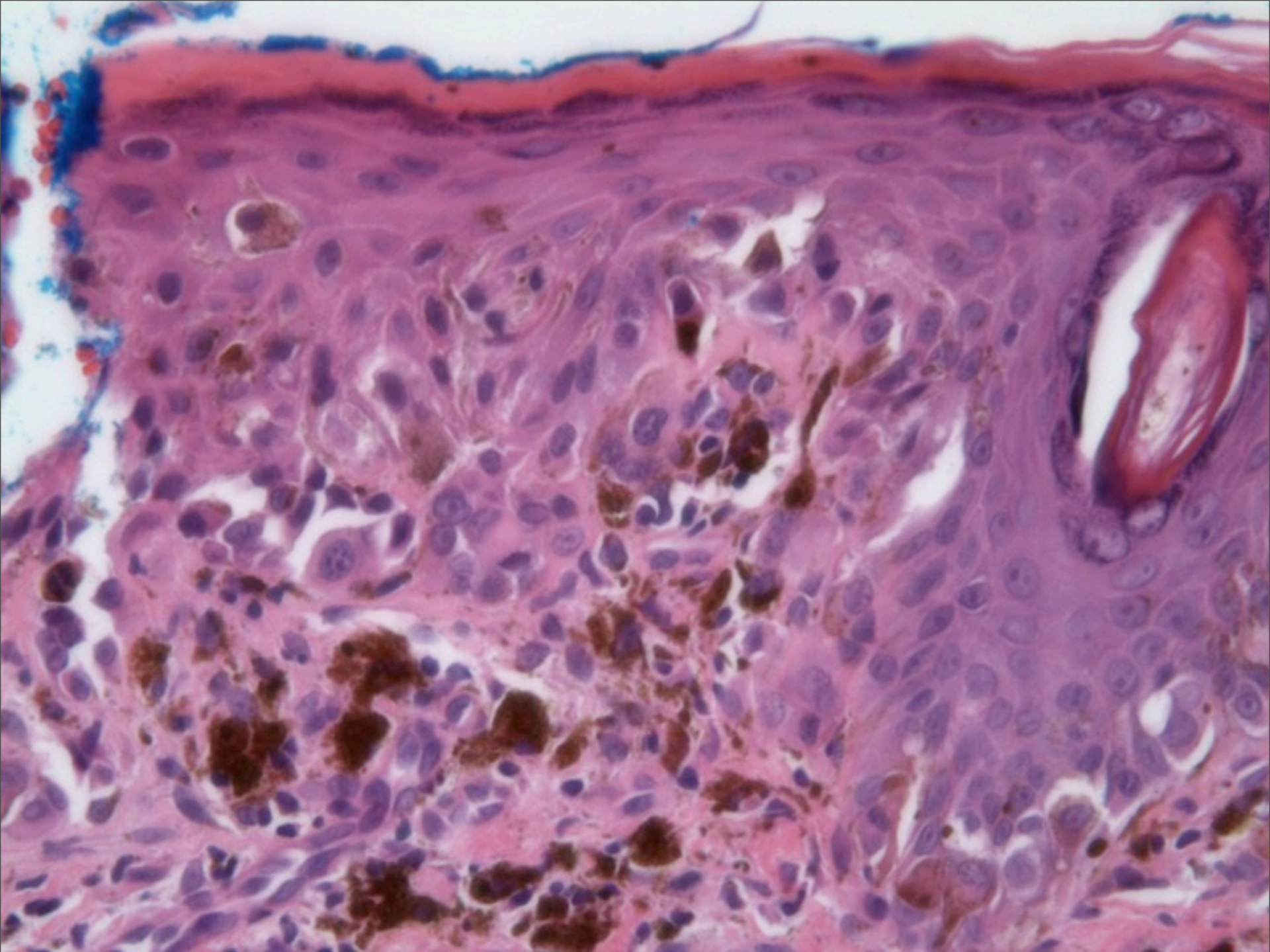






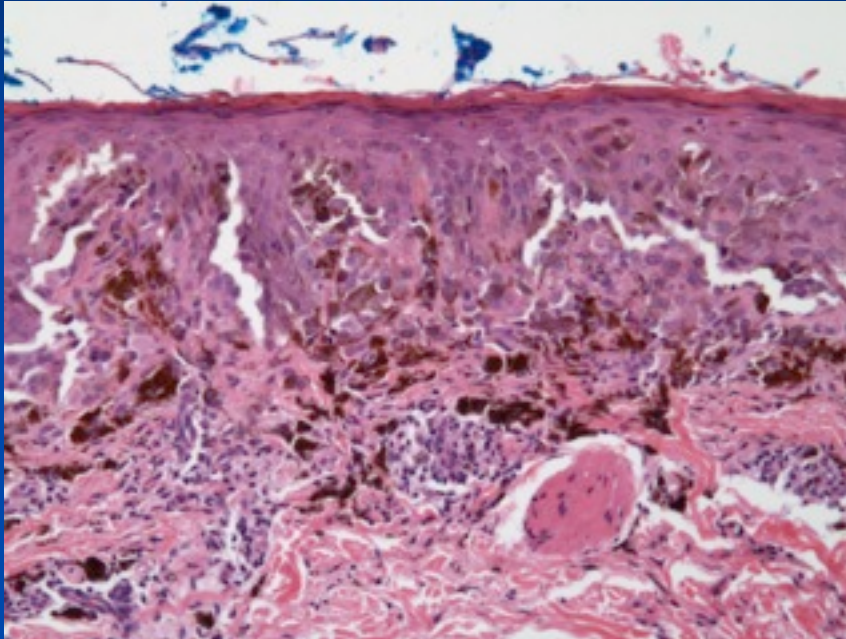




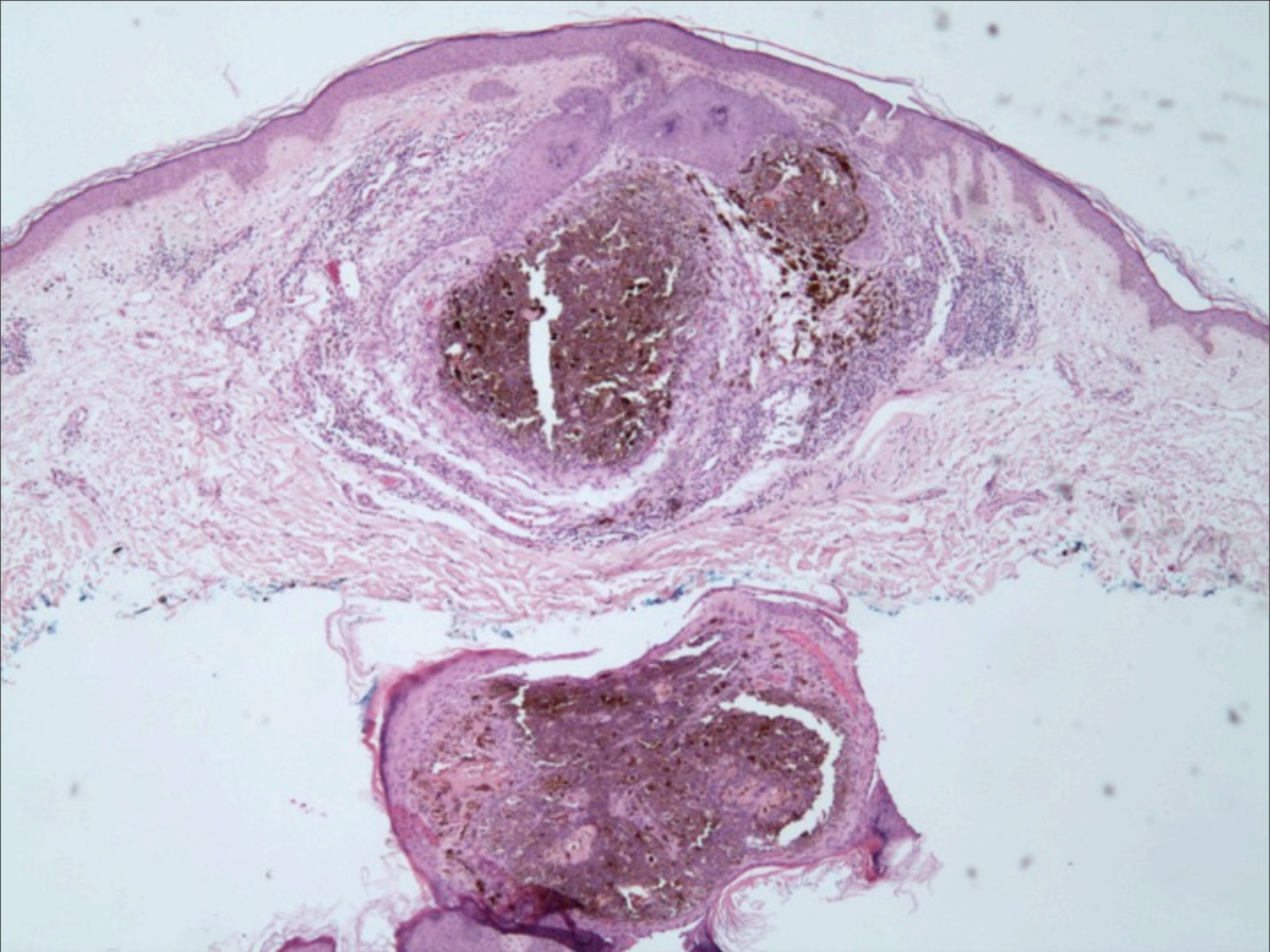


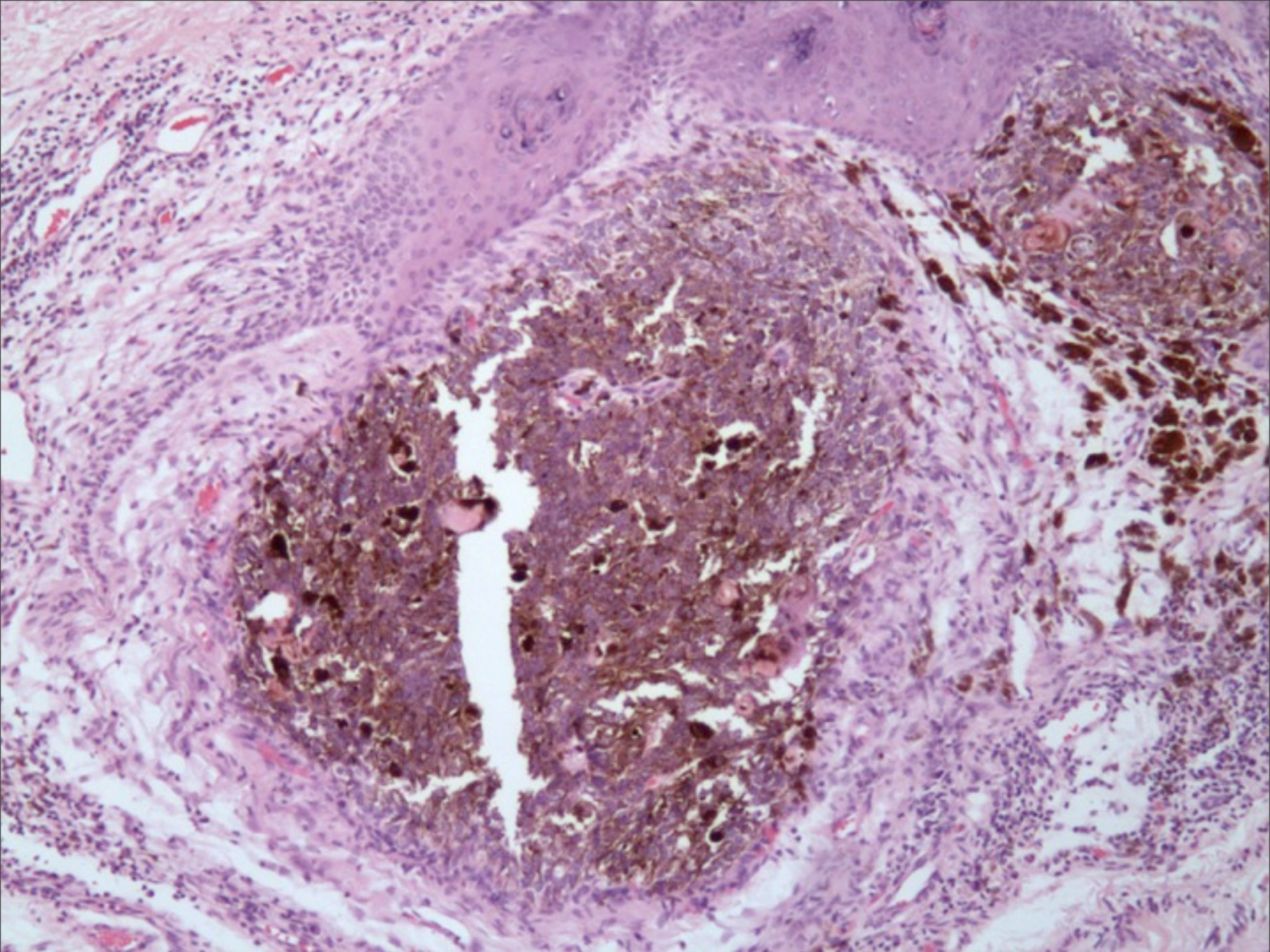
Atypical Spitz Nevus vs.

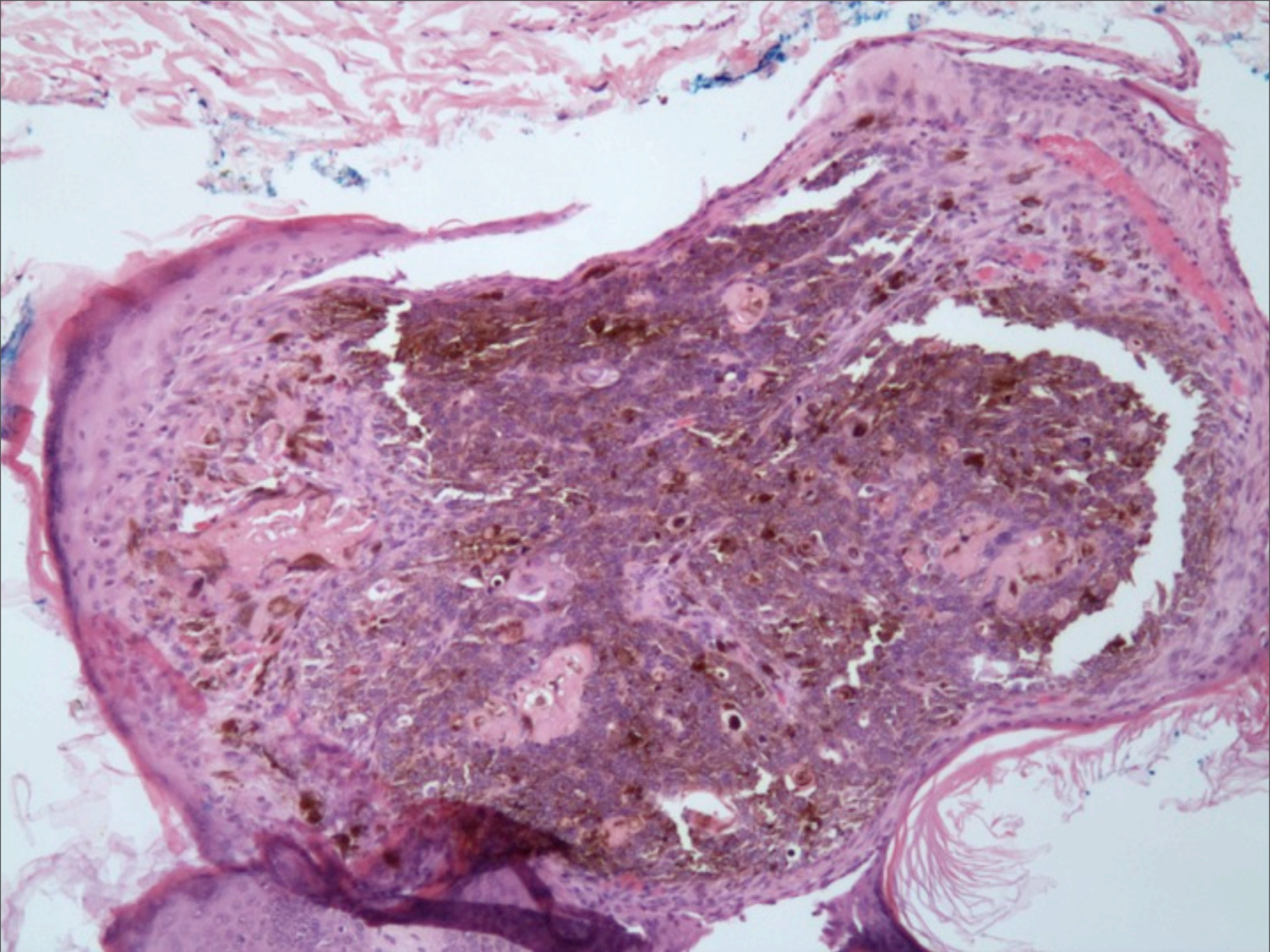
Histopathology

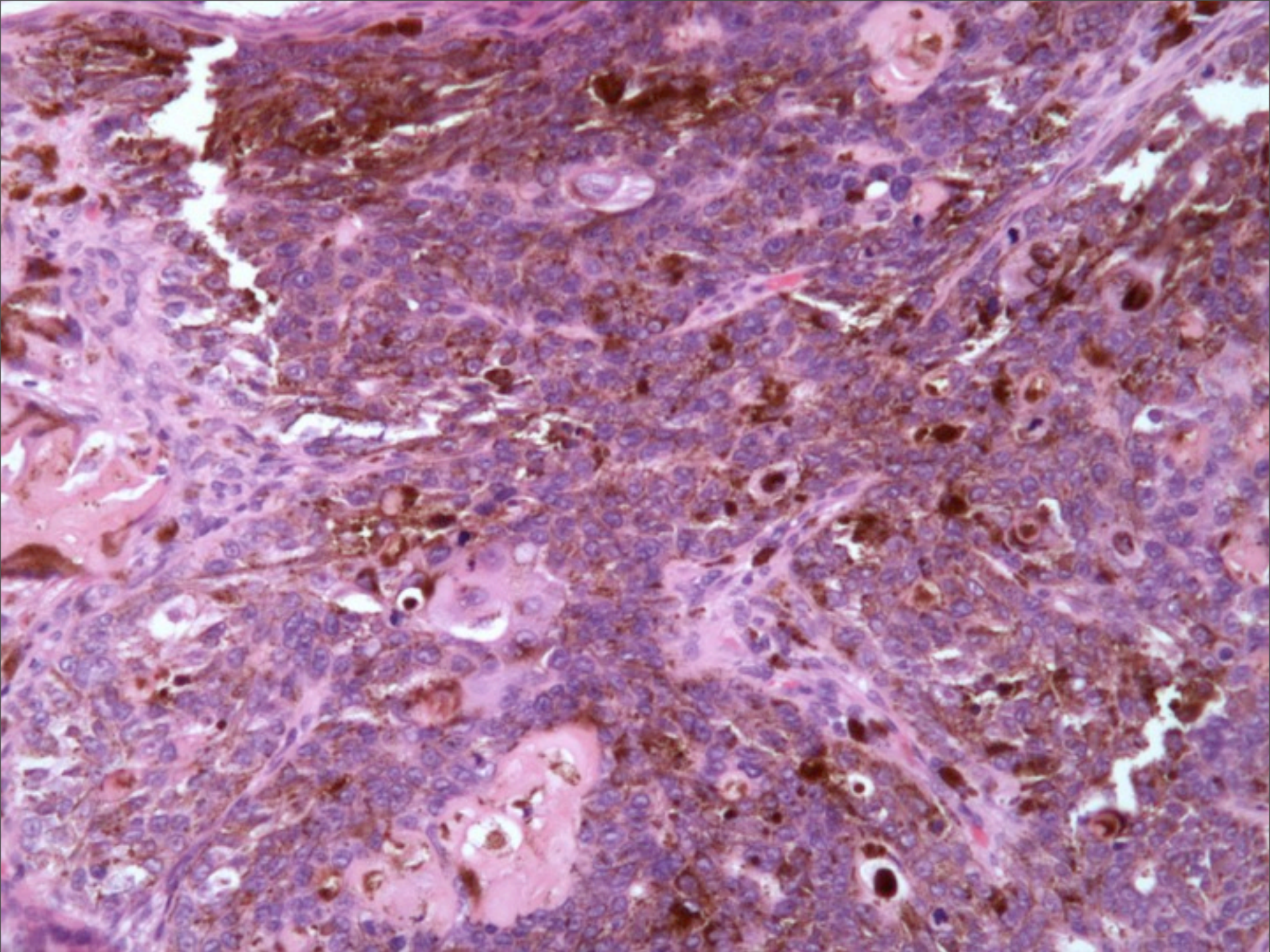


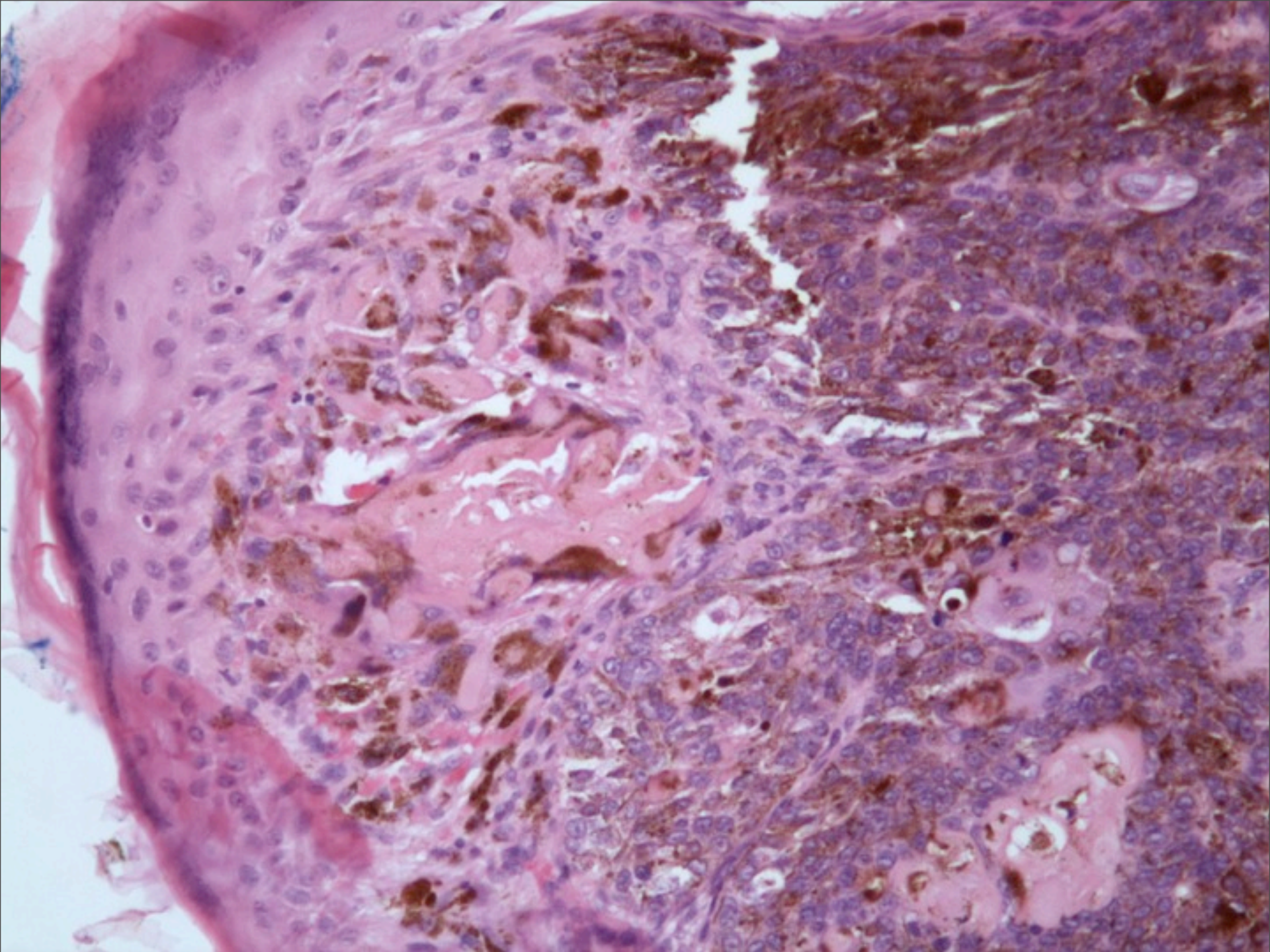
- Atypical spindled and epithelioid proliferation
- Scattered Kamino bodies
- Focal upward intraepithelial scatter
- Moderately atypical melanocytes

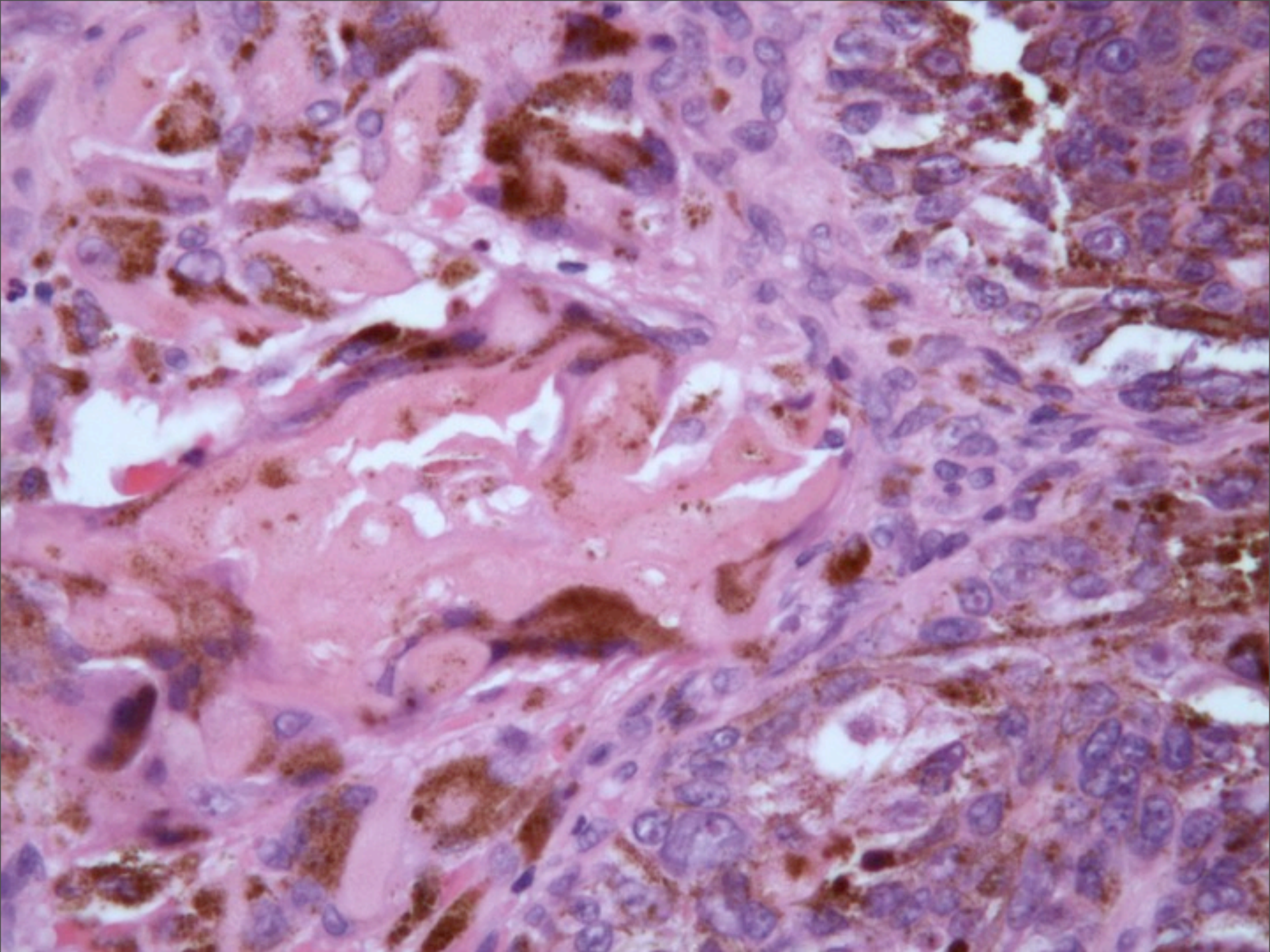


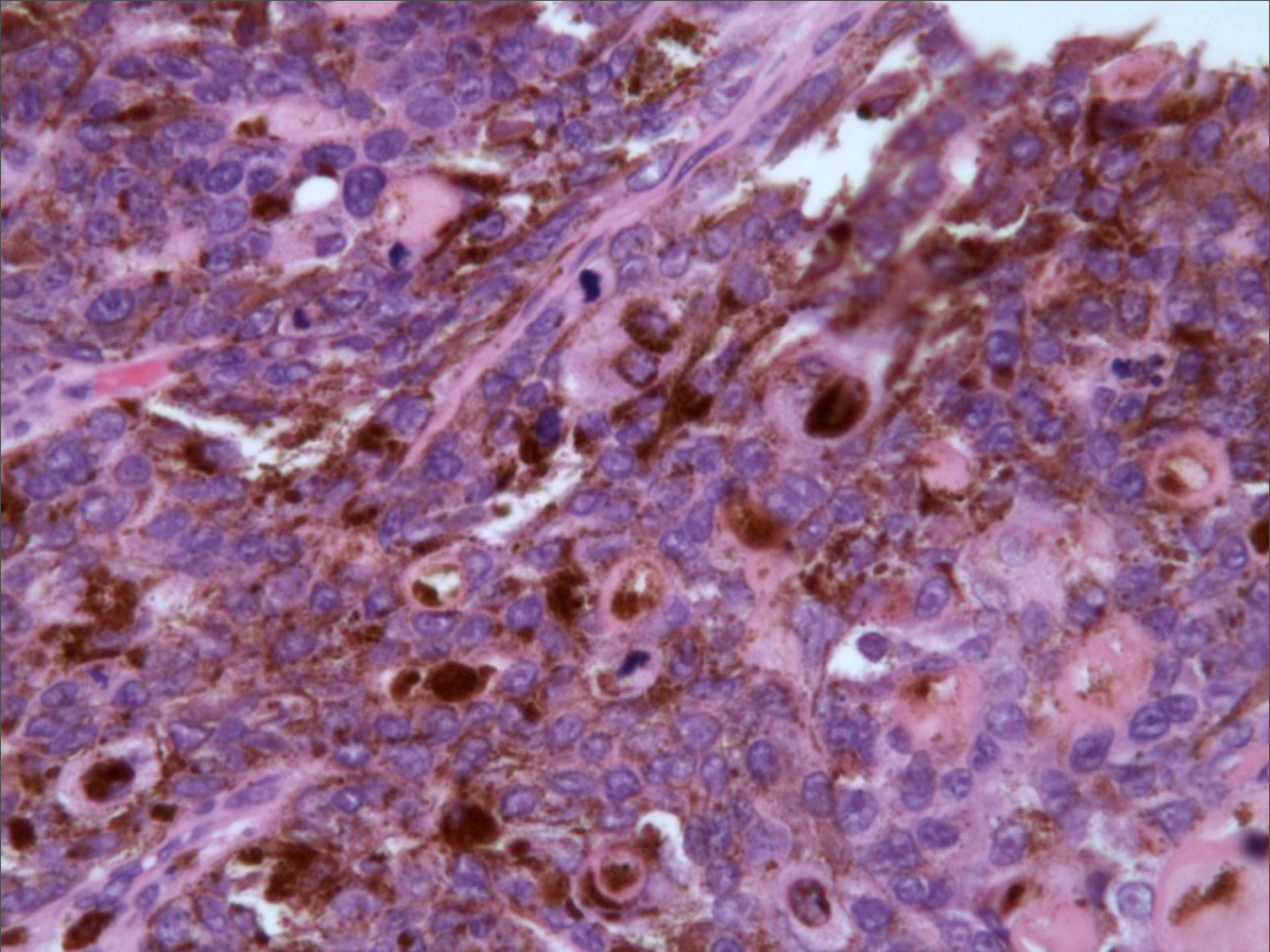


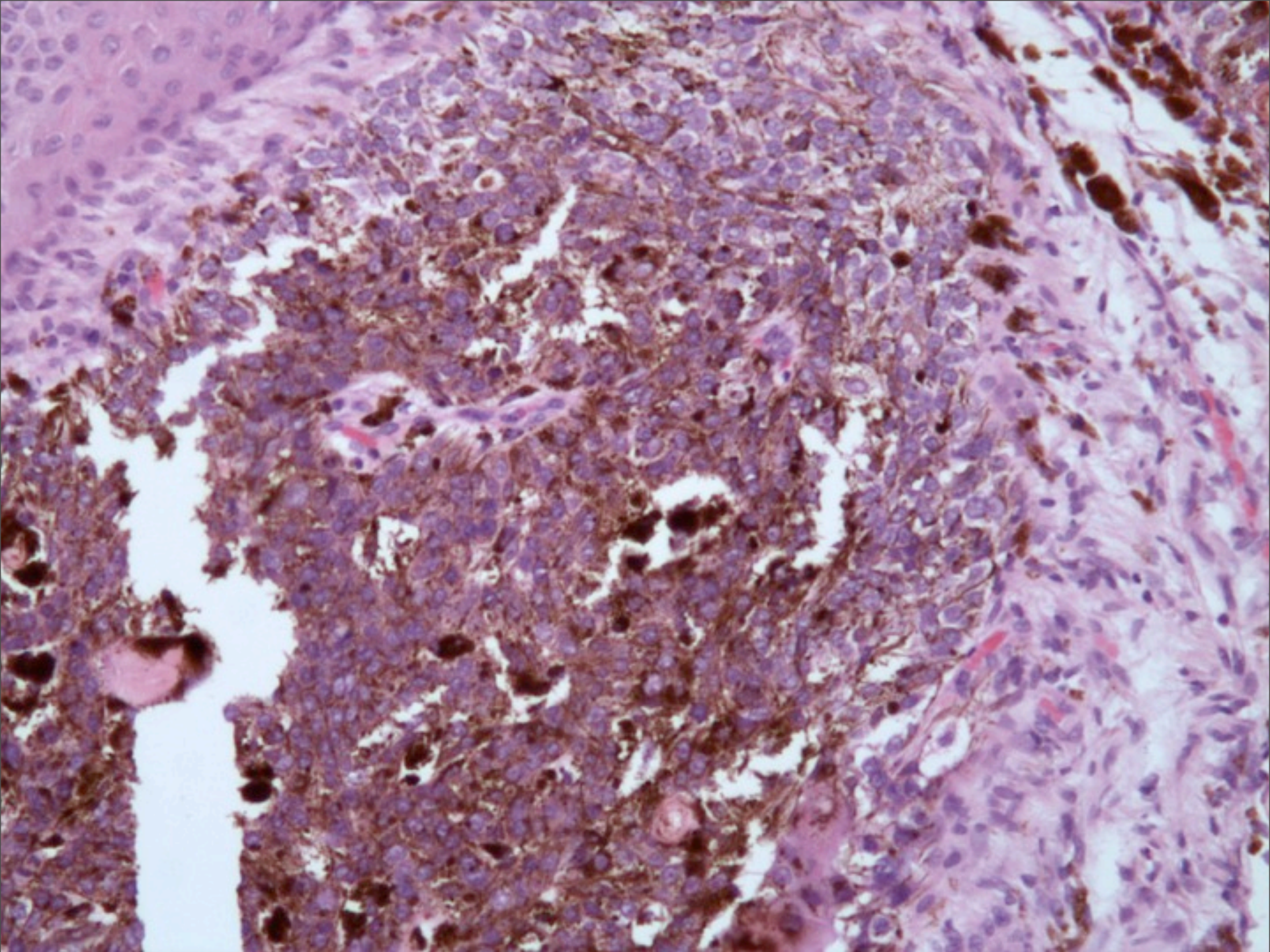


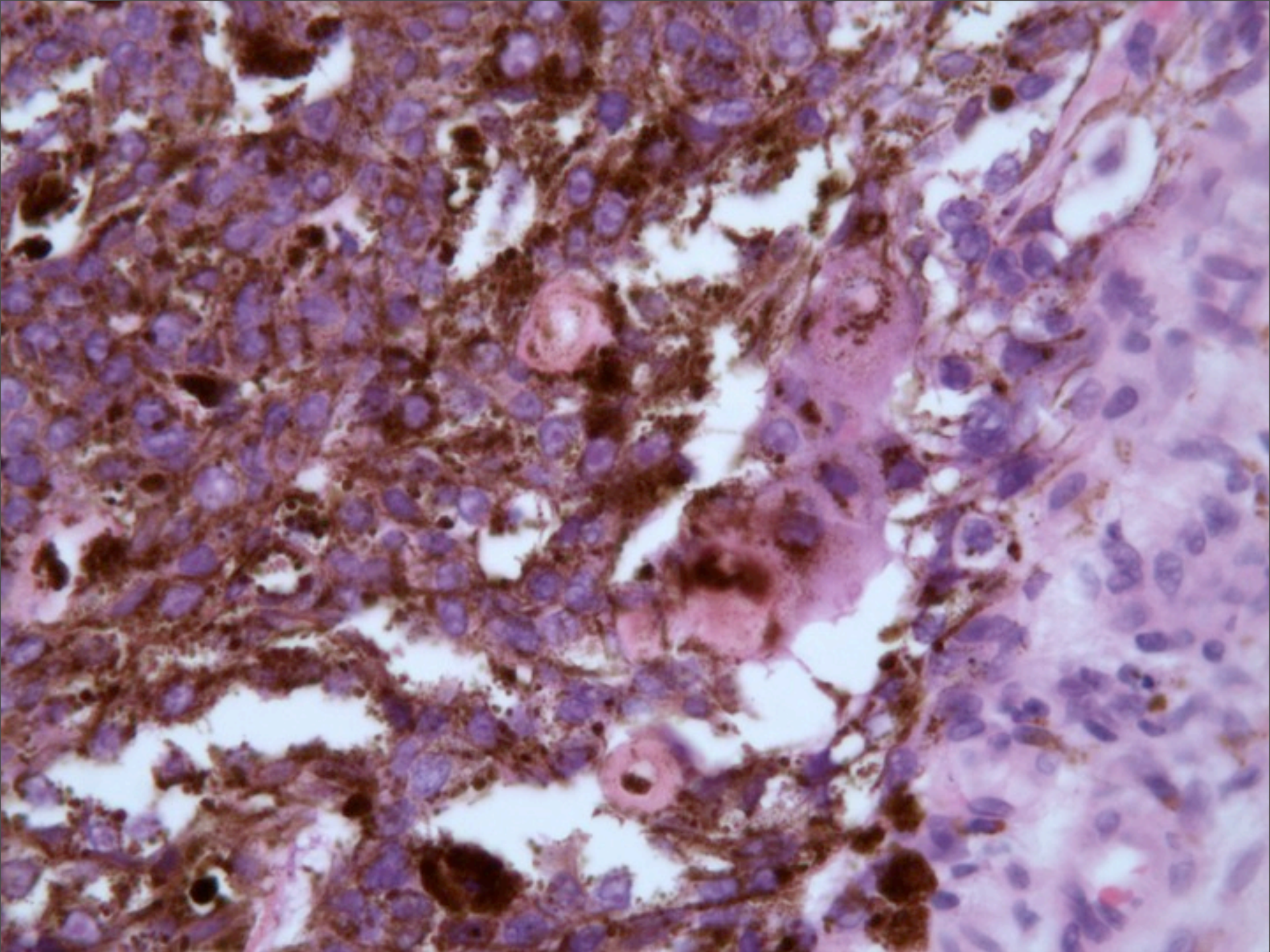


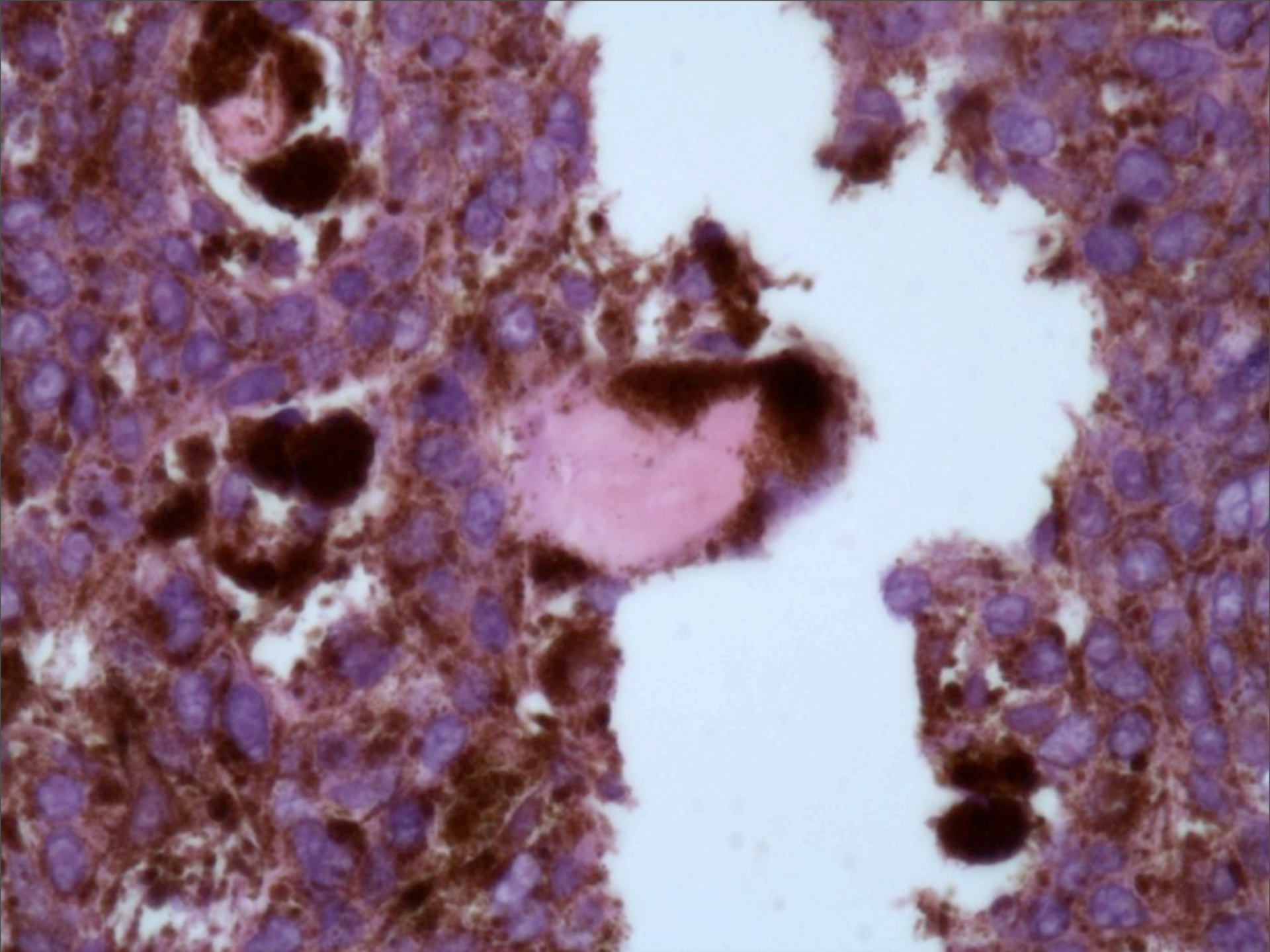






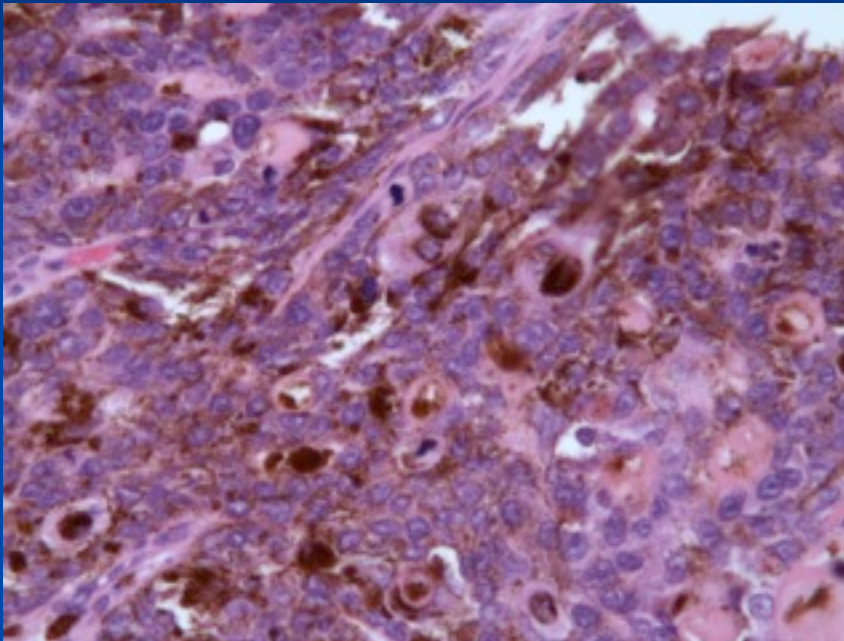






Melanocytic Matricoma

Histopathology



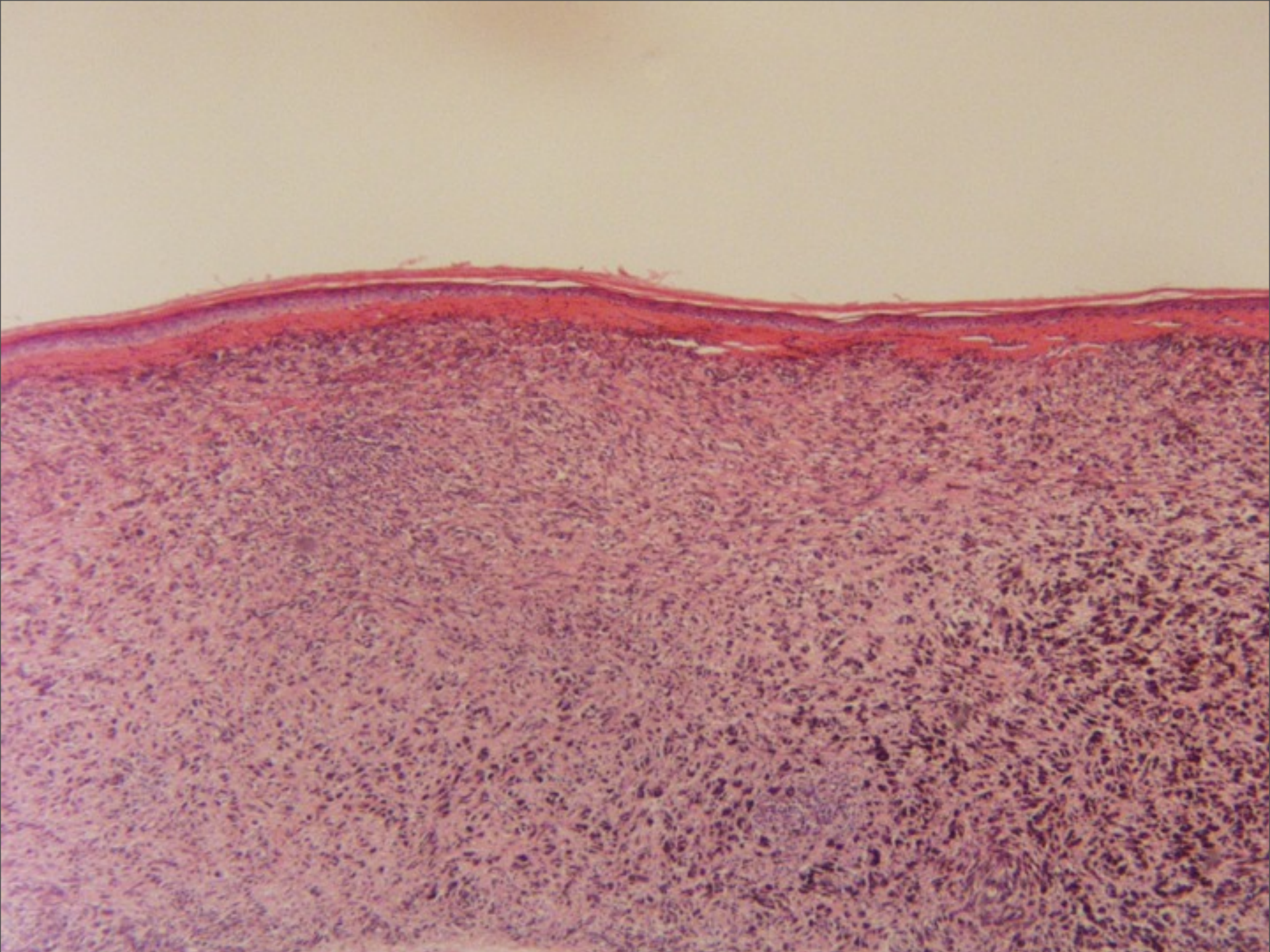
- Nodular melanized, pleomorphic, and mitotically active matrical cells
- Shadow cells
- Melanized dendritic melanocytes
- Shadow cells-keratin 13
- S-100 protein-positive dendritic cells
- No recurrence to date
- ? Two malignant cases

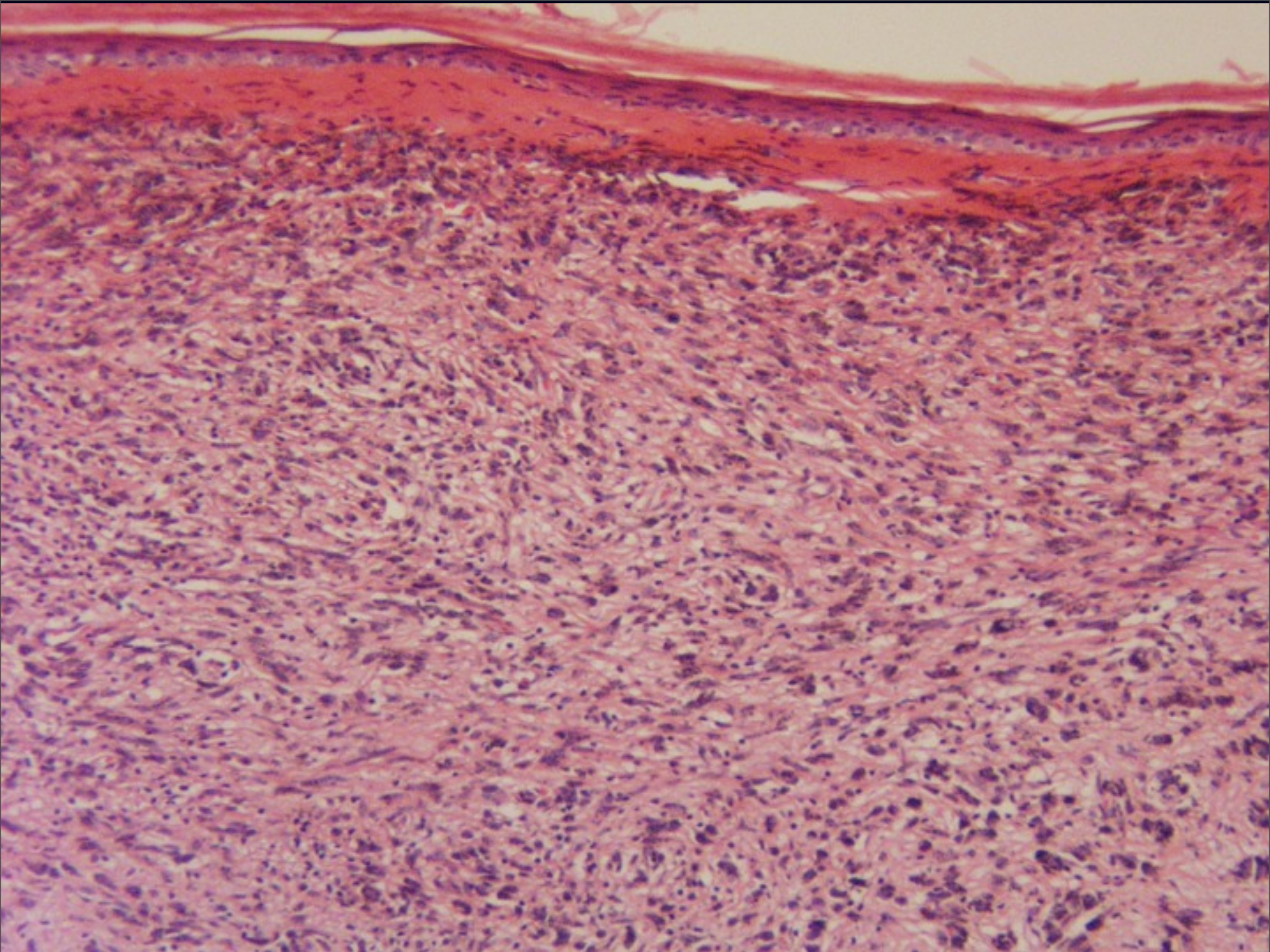
Am J Dermatopathol 1999;21:344-349

Melanocytic matricoma: a report of two cases of a new entity.

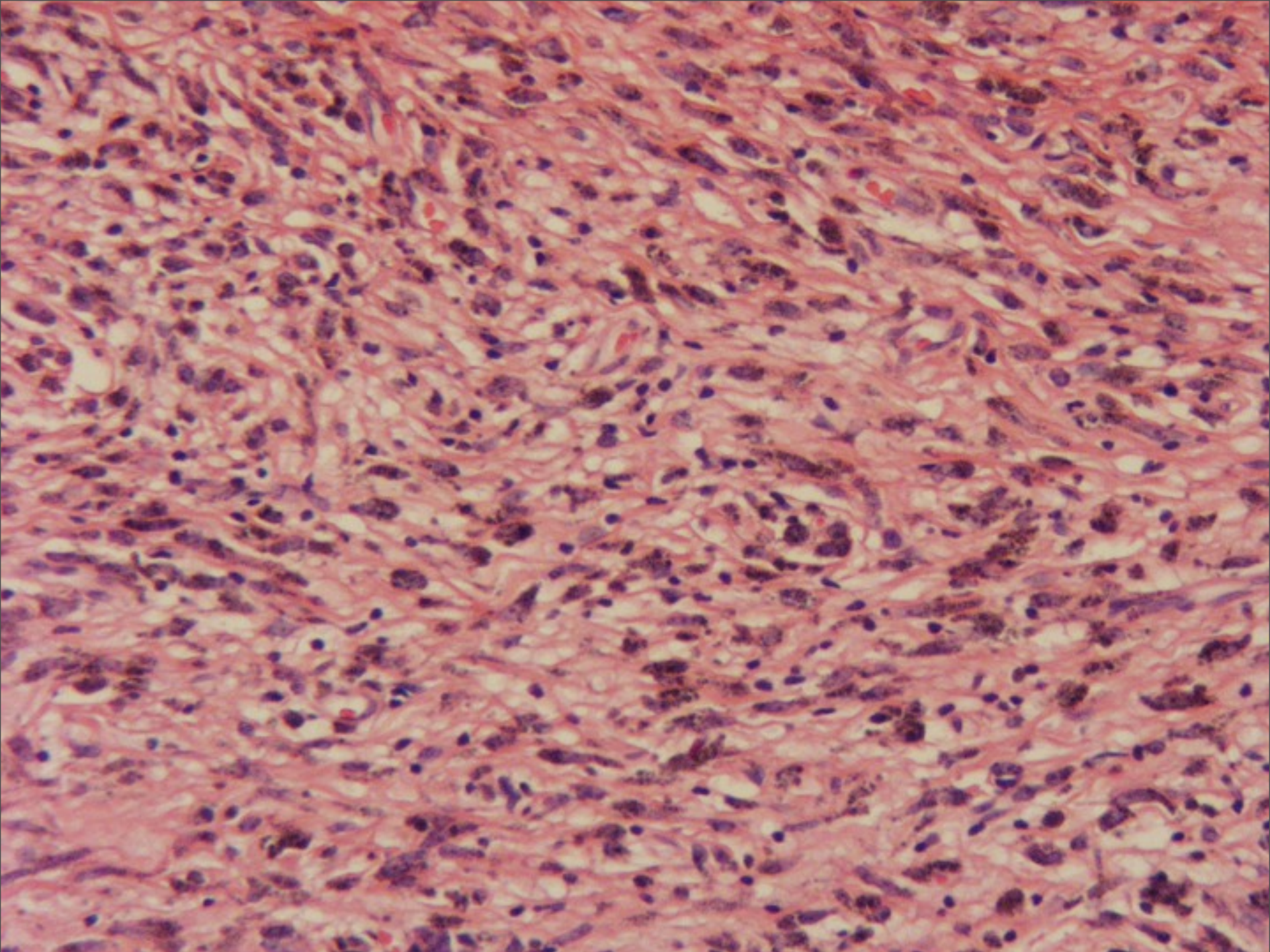
Carlson JA, Healy K, Slominski A, Mihm MC Jr.

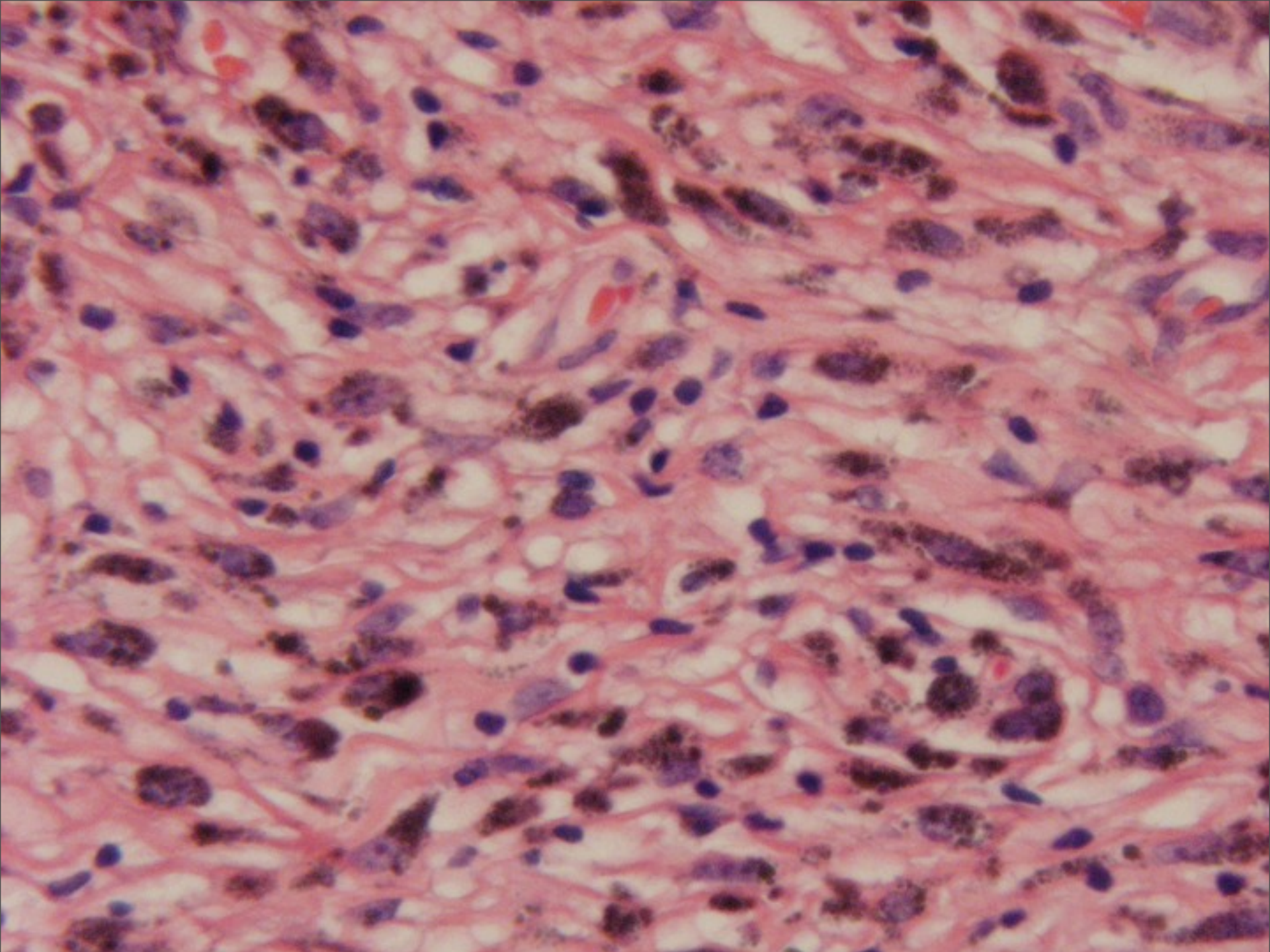
Division of Dermatopathology and Dermatology, Department of Pathology Albany Medical College, NY 12208, USA.

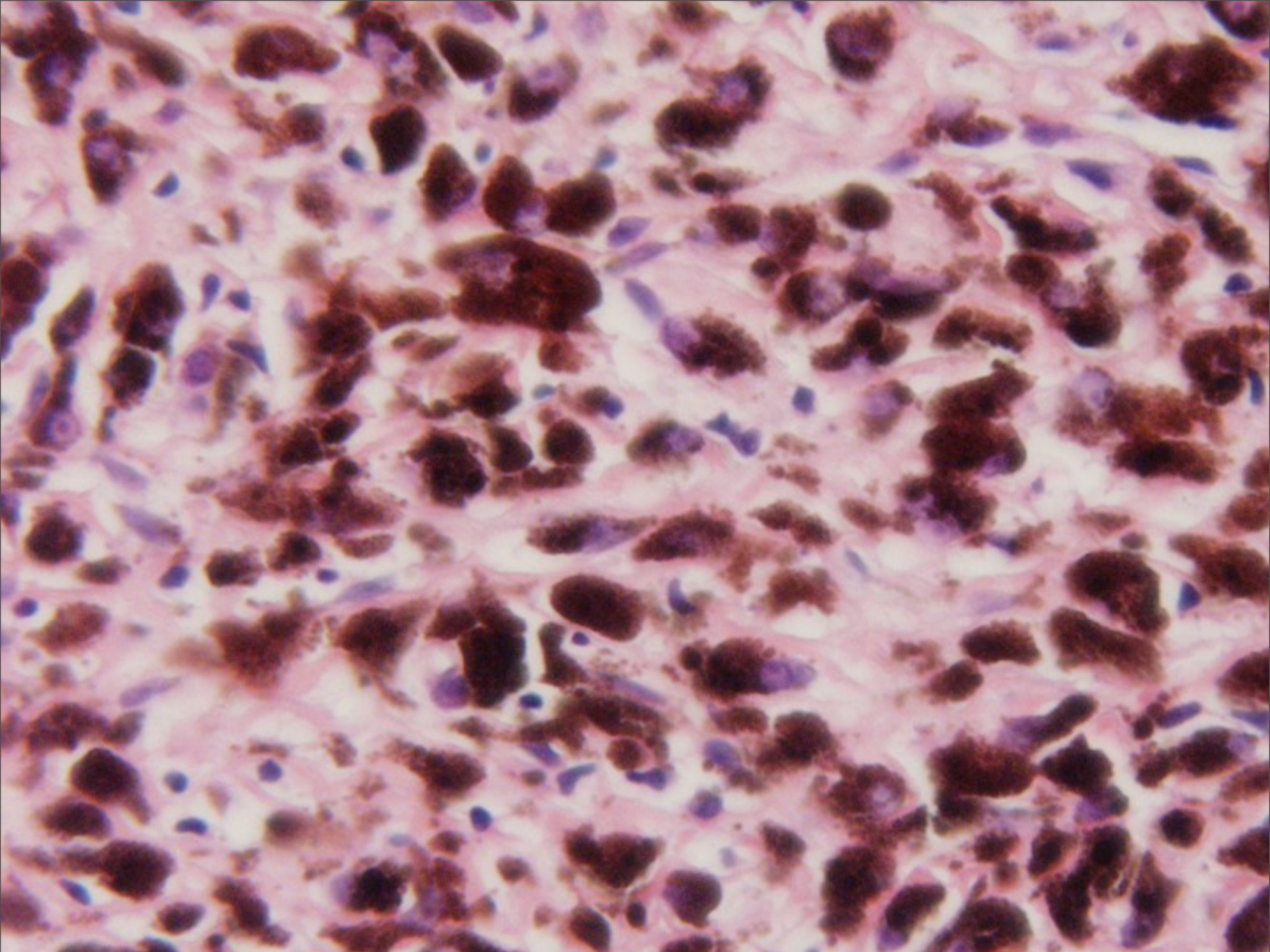




Thursday, May 23, 13

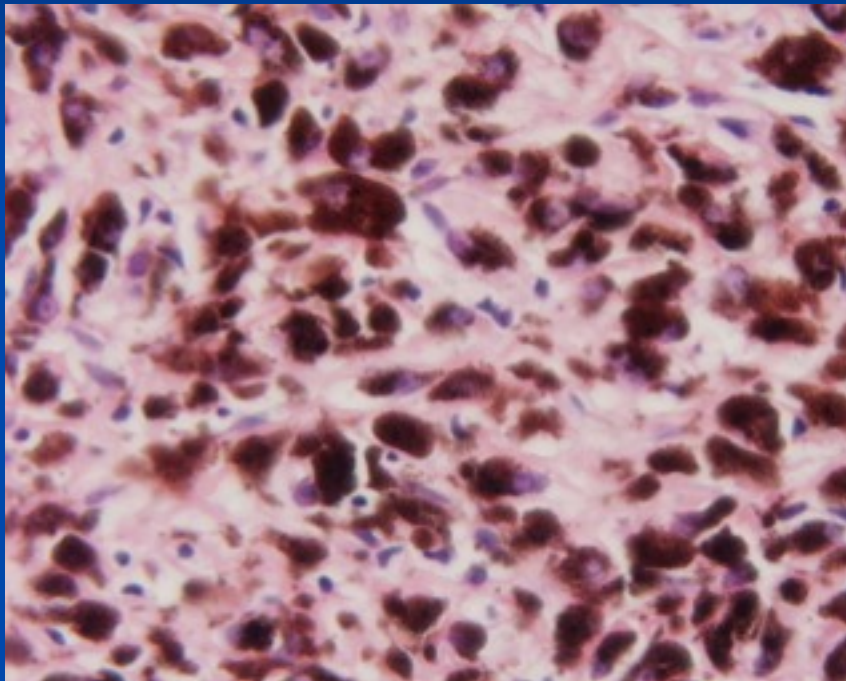






Tumoral Melanosis

Histopathology



- Nodule of melanophages
- No residual melanocytes
- May need to bleach and stain for S100/Mart1/CD68
- DDX: Regressed melanoma, regressed epithelial neoplasm